



NFMSR

NORSK FORENING FOR MUSKEL- OG SKJELETTTRADIOLOGI ©

MR KNE

i 45 minutter

Volker Lapczynski


Nestleder NFMSR

Muskel- skjelettradiolog

Unilabs Røntgen Fredrikstad

vl@Radiology.no

Disposisjon MR kne



1. har en plan «MR kne»
2. kjenner normalanatomi
3. typiske patologiske funn
4. klassisk pitfalls



Problemsentret vs Systematisk





ENG DUAL FAILURE

LAND ASAP

- ENG MODE SEL IGN
- THR LEVERS IDLE
- OPTIMUM RELIGHT SPD 300 KT

In case of a speed indication failure (volcanic ash), the pitch attitude for optimum relight speed is -4.5° (for weights above 50000 kg/110000 lb, add 1° for each 10 000 kg/22 000 lb).

At 300 knots, the aircraft can fly up to about :

- . 2 NM/1000 feet at 50 000 kg/110 000 lb
- . 2.2 NM/1000 feet at 60 000 kg/132 000 lb
- . 2.4 NM/1000 feet at 70 000 kg/154 000 lb

- EMER ELEC PWR (if EMER GEN not in line) MAN ON
- F1/HF1 \triangleleft/ATC1 USE

traffic control of the nature of the emergency, and state intentions.

no contact with air traffic control, switch to code A7700, or transmit a distress

one of the following frequencies : VHF 121.5 MHz, HF 2182 KHz or 8364 KHz.

- FA OFF THEN ON

The out of trim due to right aileron upfloat.

Reset permits rudder trim recovery, even if no indication is available.

- IF LIGHT AFTER 30 SEC :
- F STERS OFF 30 S/ON

- IF SUCCESSFUL :
- F (AVAIL) START

APU is available, it may be started when below FL 250, and the APU BLEED used engine start below FL 200.

- APU BLEED ON
- ENG MASTERS OFF 30 S/ON

Start one engine at a time.

- OPTIMUM SPEED G DOT

Green dot is displayed on the Captain's PFD. It represents the best lift-to-drag ratio.

- EARLY IN APPR (if ditching is foreseen, apply the DITCHING procedure, instead of the following) :

- CAB SECURE ORDER
- FOR LDG USE FLAP 3

As only blue hydraulic power is available, only the slats will extend, and operating times increase.

↑ AGL :

- TARGET SPEED GRVTY EXTN
- 150 KT

- AT TOUCHDOWN :

- ENG MASTERS OFF
- APU MASTER SW OFF
- EVAC INITIATE

- BAT 1 +2

(If time permits before leaving aircraft) OFF

Batteries are left ON, until leaving the aircraft, to ensure cabin communications.

NOTE : *Keep batteries on for at least 10 seconds, after switching the ENG MASTERS to OFF, to allow complete closure of the fuel LP valves.*

MR kne

Fremre kammer / patellofemorale ledd	
Patella Posisjon	
- vertikal	baja/ N 1.1 / alta > 1.3
- aksial	lat/med/sub/luksert
Størrelse	liten/N/magna
Form	Wiberg type 1/2/3
Retropatelær bruskk	Outerbridge
lett	uregelm. signal. N tykkelse 1
moderat	<50% 2
markert	>50% 3
blottlagt	blottlagt ben 4
Trochlea	N/flat <3mm
grop dybde/brusk	
Quadriceps sene og Q. fettpute	N/tendinopati/ruptur/enthesopati
Ligamentum patellae	N/tendinopati/ruptur/enthesopati
Hoffas fettpute	N/ødem/ruptur

Posteromediale hjørne PMC	
Semimembranosus sene	N/tendinopati/ruptur
Post. oblique lig. POL	N/tendinopati/ruptur
PM leddkapsel	N/ruptur

Posterolaterale hjørne PLC	
1 Popliteus sene	N/tendinopati/part. ruptur
2 Biceps femoris senen	N/tendinopati/part. ruptur
3 Popliteofibulare ligament	N/tendinopati/ruptur
4 LCL	N/tendinopati/ruptur
5 Tractus iliotibialis TIB	N/tendinopati/ruptur
6 PL leddkapsel	N/ruptur

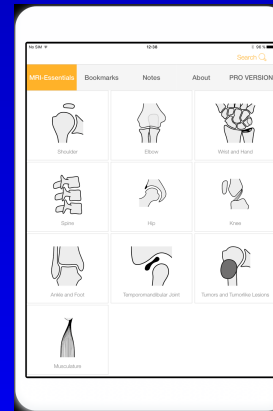
Mediale og laterale kammer	
Benmarg	N/ødem/sklerose/fokale lesjoner
Leddoverflate	jevn/uregelm/påleiring
Brusk	Outerbridge
lett	uregelm. signal. N tykkelse 1
moderat	<50% 2
markert	>50% 3
blottlagt	blottlagt ben 4
Menisk	høysignal uten ruptur
parameniskial cyste	skrått/horisontal
- degenerativ	radial/longitudinal
- traumatisk	flik/bøttehanke/Parrot beak
- lokalisering	ytre/midtre/inner

Ligamenter	
Fremre korsbånd ACL	N/mucoid degen/ruptur
Bakre korsbånd PCL	N/mucoid degen/ruptur
Med. kollaterallig MCL m-femoral/m-tibial	N/fortykket/høysignal/ruptur
Lat. kollaterallig LCL	N/fortykket/høysignal/ruptur

Bløtvev	
Muskulatur	N/ødem/ruptur/hematom
Væske	hydrops
Bakers cyste	størrelse/lekkasje
Gastroknemius/Pes anserinus	størrelse/synovitt/chondromatose
Nevro vaskulære strukturer	N/aneurysma/nevrinom

Volker Lapczynski © 2018
www.radiology.no


MRI-Essentials



ESSR.org



Sjekkliste



A) Alder/kjønn

B) Bilder til sammenlikning?

C) Røntgen?

D) Dokumentasjon
Henvisning

1. Fremre kammer

2. Mediale/Lat. kammer

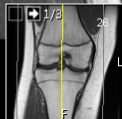
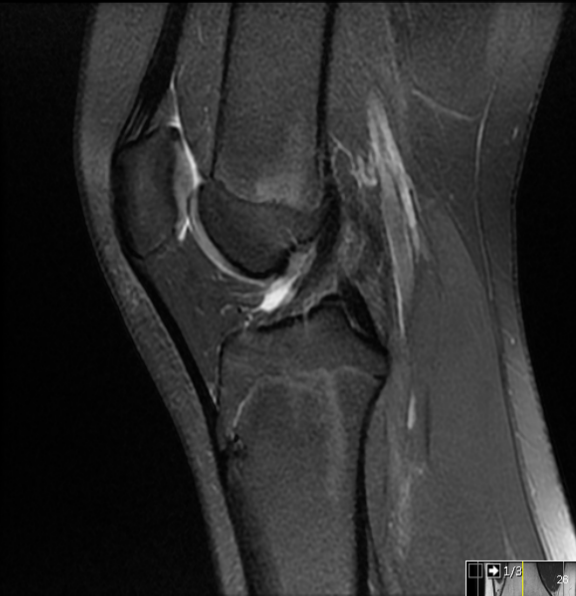
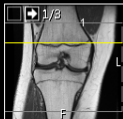
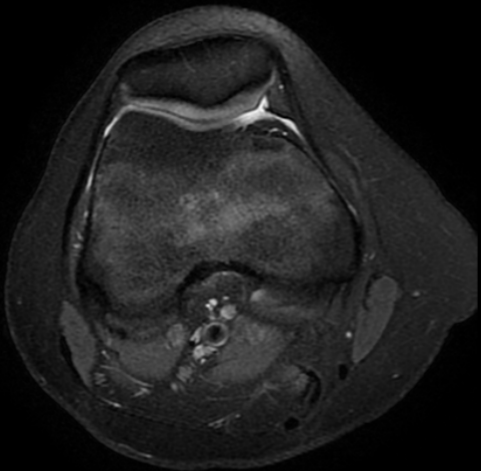
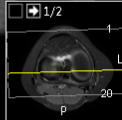
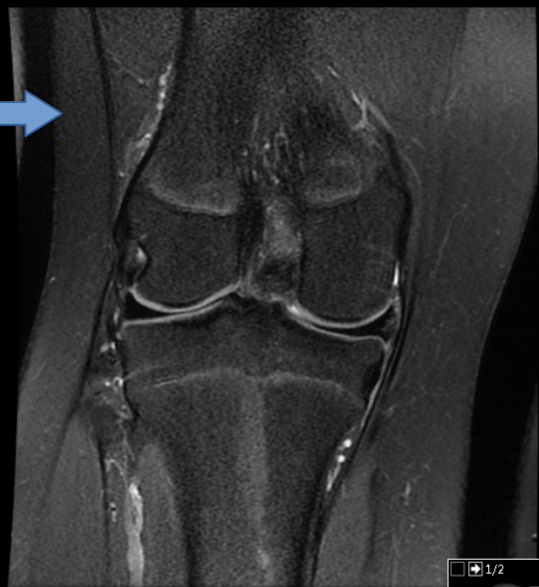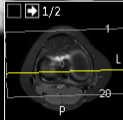
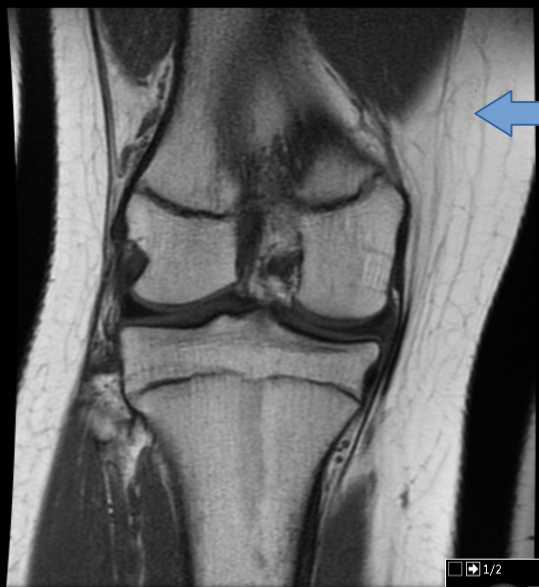3. Ligamenter

4. Bløtvev

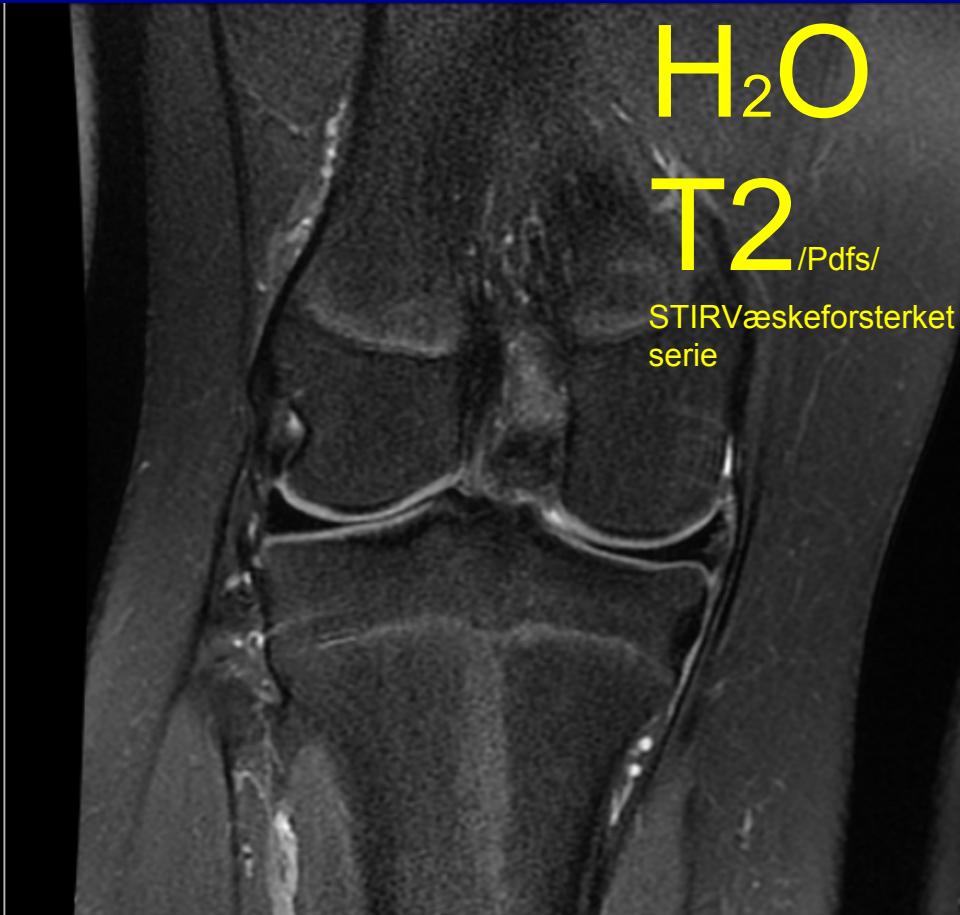
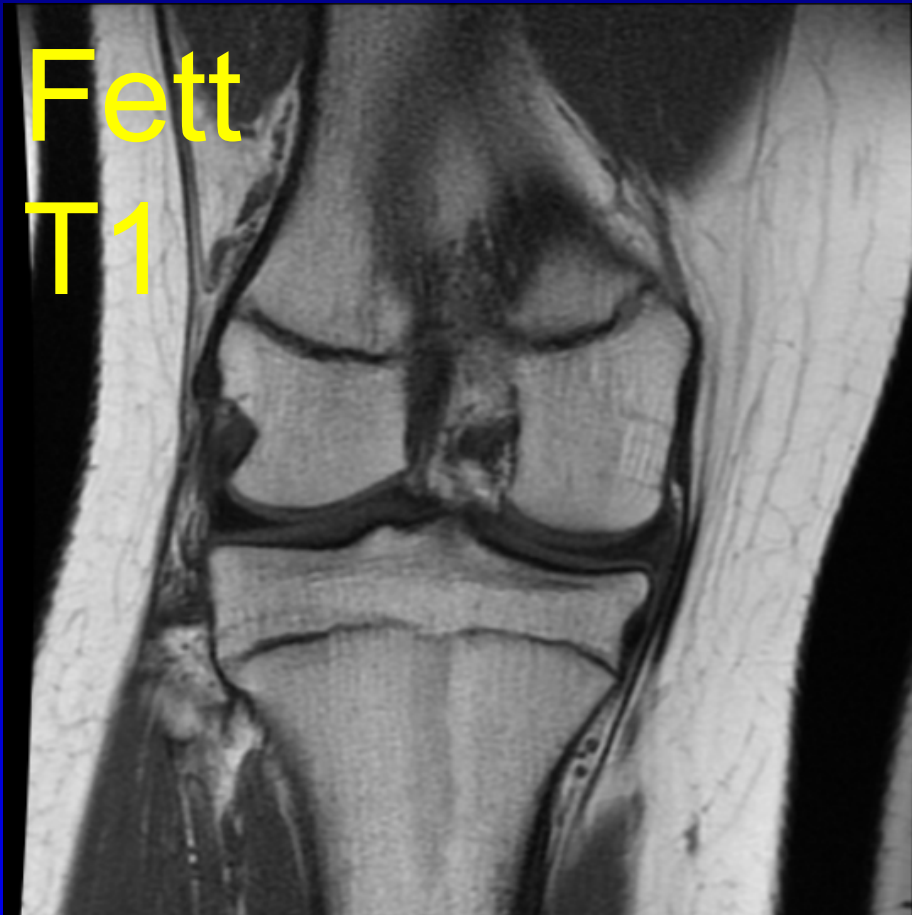
5. Posteromediale hjørne

6. Posterolaterale hjørne





MR easy for «Radiologer»



MRI= Fett + H2O + Kalk

Fremre kammer / patellofemorale ledd

Patella Posisjon

- vertikal baja/ N 1.1 / alta > 1.3

- aksial lat/med/sub/luksert

Størrelse liten/N/magna

Form Wiberg type 1/2/3

Retropatelær brusk Outerbridge

lett uregelm. signal. N tykkelse 1

moderat <50% 2

markert >50% 3

blottlagt blottlagt ben 4

Trochlea N/flat <3mm

grop dybde/brusk

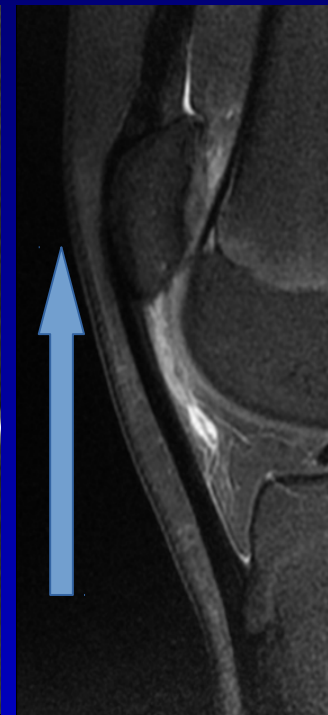
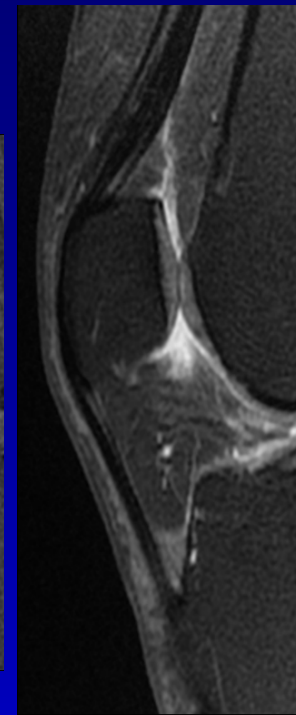
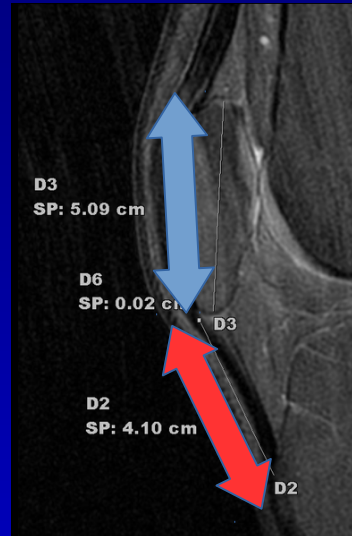
Quadriceps sene N/tendinopati/

og Q. fettpute ruptur/enthesopati

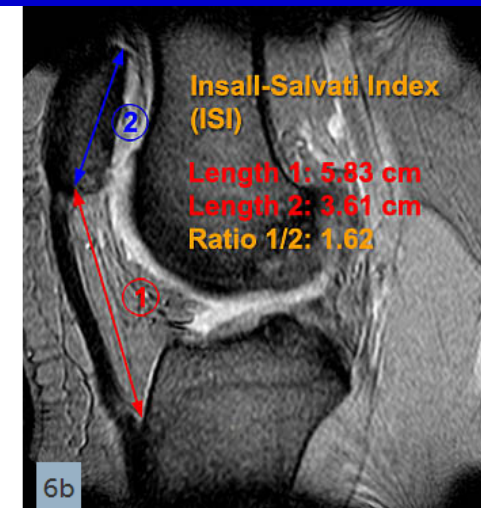
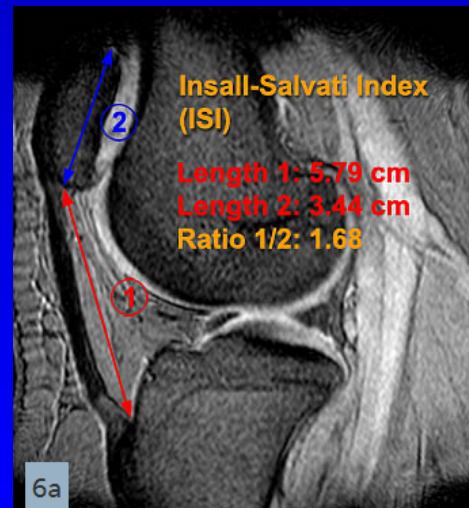
Ligamentum patellae N/tendinopati/

ruptur/enthesopati

Hoffas fettpute N/ødem/ruptur



Ratio 1/2: 1,1 < normal > 1,3



Fremre kammer / patellofemorale ledd

Patella Posisjon

- vertikal baja/ N 1.1 / alta > 1.3

- aksial lat/med/sub/luksert

Størrelse liten/N/magna

Form Wiberg type 1/2/3

Retropatelær brusk Outerbridge

lett uregelm. signal. N tykkelse 1

moderat <50% 2

markert >50% 3

blottlagt blottlagt ben 4

Trochlea N/flat <3mm

grop dybde/brusk

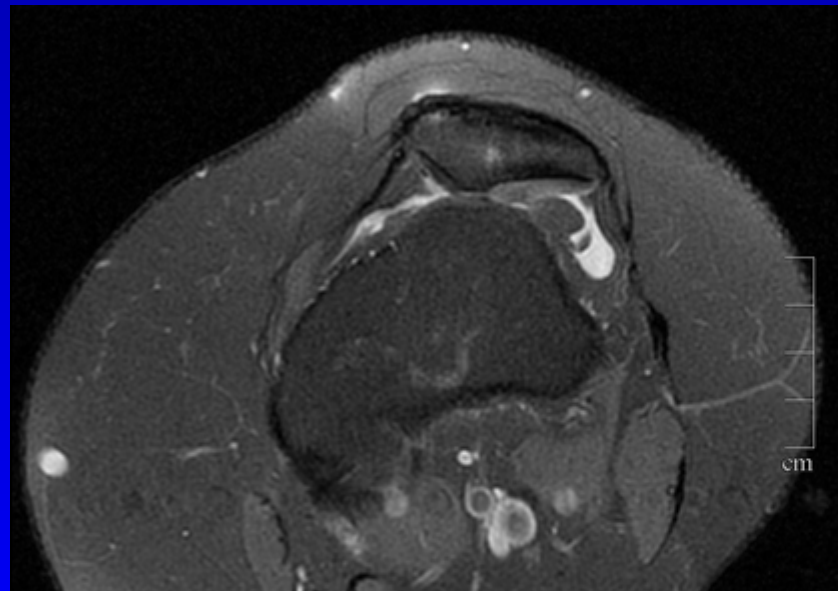
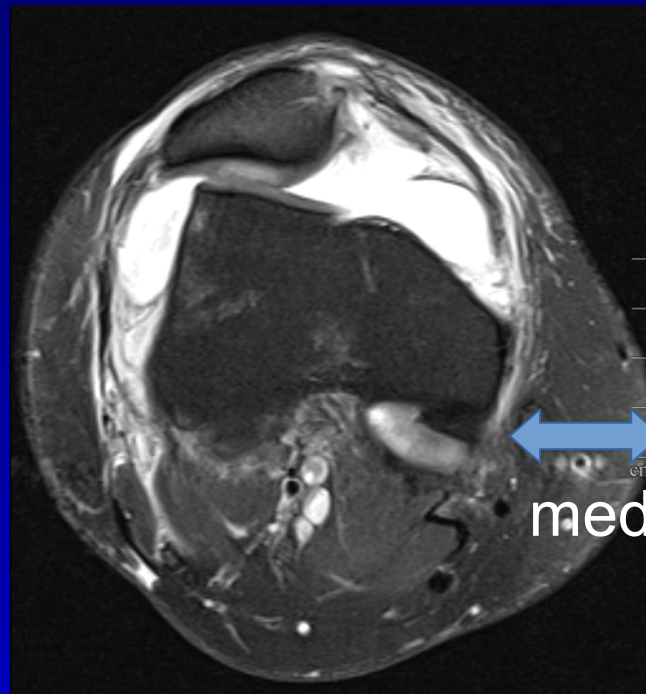
Quadriceps sene N/tendinopati/

og Q. fettpute ruptur/enthesopati

Ligamentum patellae N/tendinopati/

ruptur/enthesopati

Hoffas fettpute N/ødem/ruptur



Fremre kammer / patellofemorale ledd

Patella Posisjon

- vertikal baja/ N 1.1 / alta > 1.3
- aksial lat/med/sub/luksert

Størrelse liten/N/magna

Form Wiberg type 1/2/3

Retropatelær brusk Outerbridge

lett uregelm. signal. N tykkelse 1

moderat <50% 2

markert >50% 3

blottlagt blottlagt ben 4

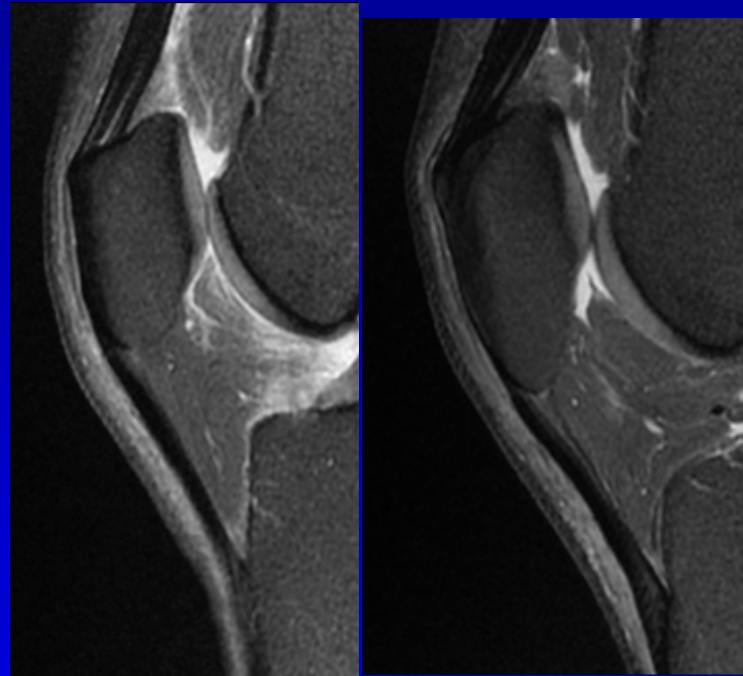
Trochlea N/flat <3mm

grop dybde/brusk

**Quadriceps sene
og Q. fettpute** N/tendinopati/
ruptur/enthesopati

Ligamentum patellae N/tendinopati/
ruptur/enthesopati

Hoffas fettpute N/ødem/ruptur



Fremre kammer / patellofemorale ledd

Patella Posisjon

- vertikal baja/ N 1.1 / alta > 1.3
- aksial lat/med/sub/luksert

Størrelse liten/N/magna

Form Wiberg type 1/2/3

Retropatelær brusk Outerbridge

lett uregelm. signal. N tykkelse 1

moderat <50% 2

markert >50% 3

blottlagt blottlagt ben 4

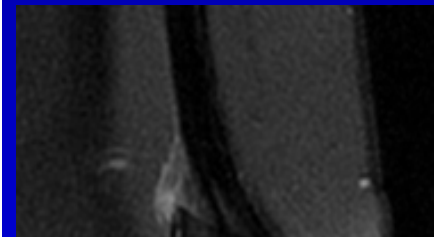
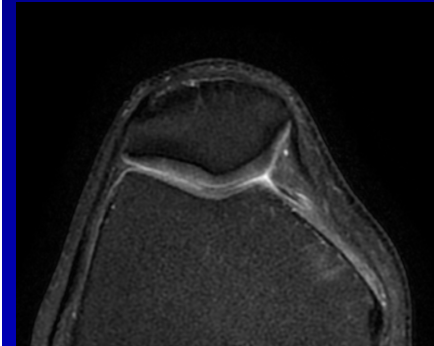
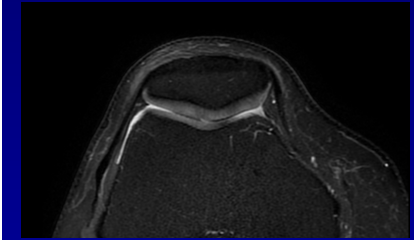
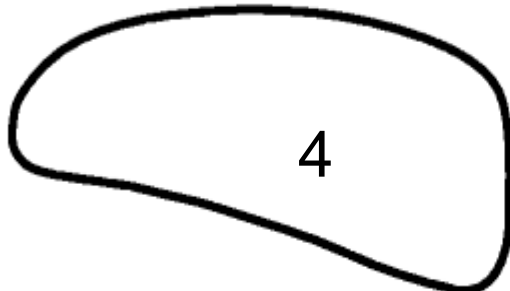
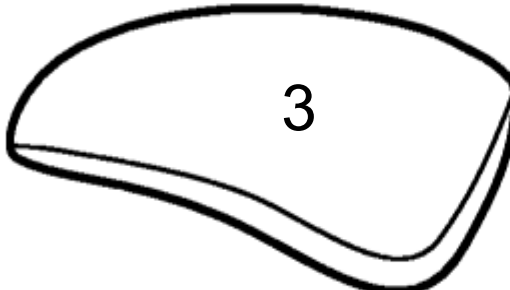
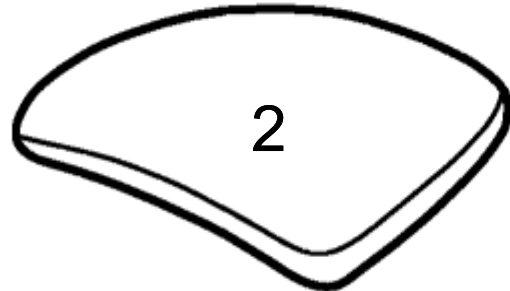
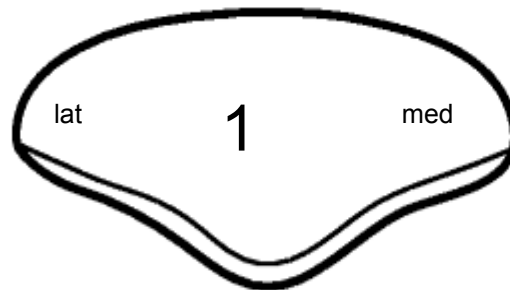
Trochlea N/flat <3mm

grop dybde/brusk

Quadriceps sene N/tendinopati/
og Q. fettpute ruptur/enthesopati

Ligamentum patellae N/tendinopati/
ruptur/enthesopati

Hoffas fettpute N/ødem/ruptur



Lat./medialfasett: konkav/konveks, symmetrisk, størrelse.

Fremre kammer / patellofemorale ledd

Patella Posisjon

- vertikal baja/ N 1.1 / alta > 1.3
- aksial lat/med/sub/luksert

Størrelse liten/N/magna

Form Wiberg type 1/2/3

Retropatelær brusk Outerbridge

lett uregelm. signal. N tykkelse 1

moderat <50% 2

markert >50% 3

blottlagt blottlagt ben 4

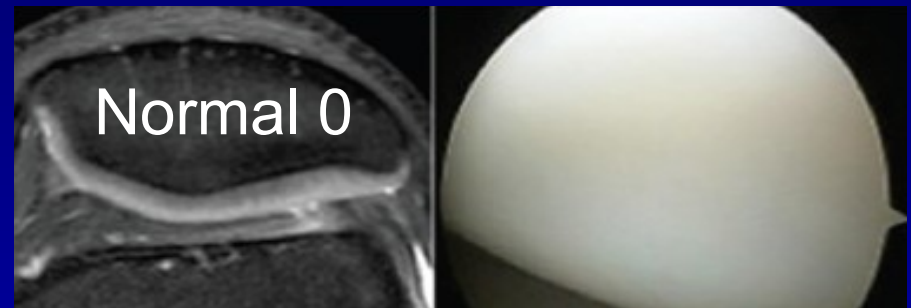
Trochlea N/flat <3mm

grop dybde/brusk

Quadriceps sene N/tendinopati/
og Q. fettpute ruptur/enthesopati

Ligamentum patellae N/tendinopati/
ruptur/enthesopati

Hoffas fettpute N/ødem/ruptur



Normal 0

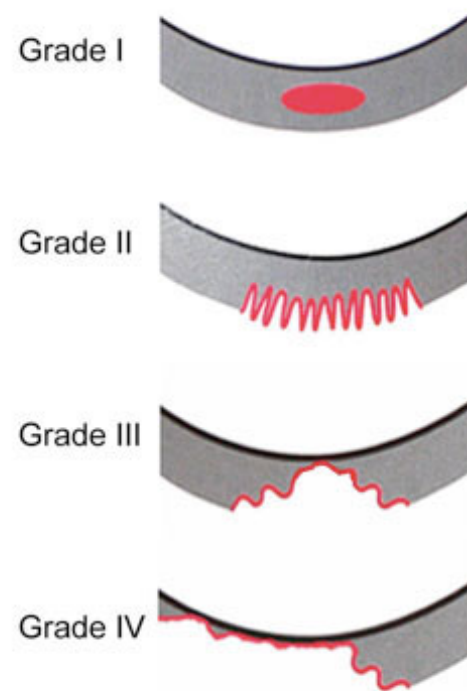


Figure 1.
Outerbridge classification of cartilage injury:
Grade 1: Softening
Grade 2: Fibrillation
Grade 3: Partial thickness
Grade 4: Full thickness with exposed bone.

Fremre kammer / patellofemorale ledd

Patella Posisjon

- vertikal baja/ N 1.1 / alta > 1.3

- aksial lat/med/sub/luksert

Størrelse liten/N/magna

Form Wiberg type 1/2/3

Retropatelær brusk Outerbridge

lett uregelm. signal. N tykkelse 1

moderat <50% 2

markert >50% 3

blottlagt blottlagt ben 4

Trochlea N/flat <3mm

grop dybde/brusk

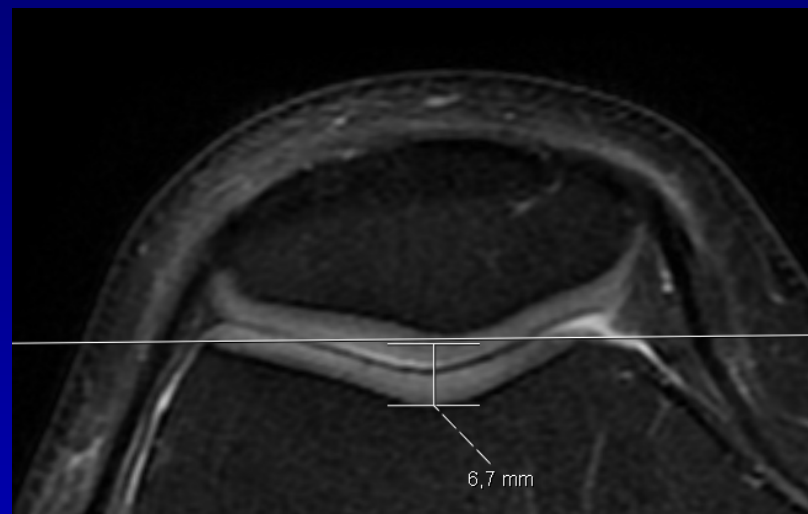
Quadriceps sene N/tendinopati/

og Q. fettpute ruptur/enthesopati

Ligamentum patellae N/tendinopati/

ruptur/enthesopati

Hoffas fettpute N/ødem/ruptur



Fremre kammer / patellofemorale ledd

Patella Posisjon

- vertikal baja/ N 1.1 / alta > 1.3
- aksial lat/med/sub/luksert

Størrelse liten/N/magna

Form Wiberg type 1/2/3

Retropatelær brus Outerbridge

lett uregelm. signal. N tykkelse 1

moderat <50% 2

markert >50% 3

blottlagt blottlagt ben 4

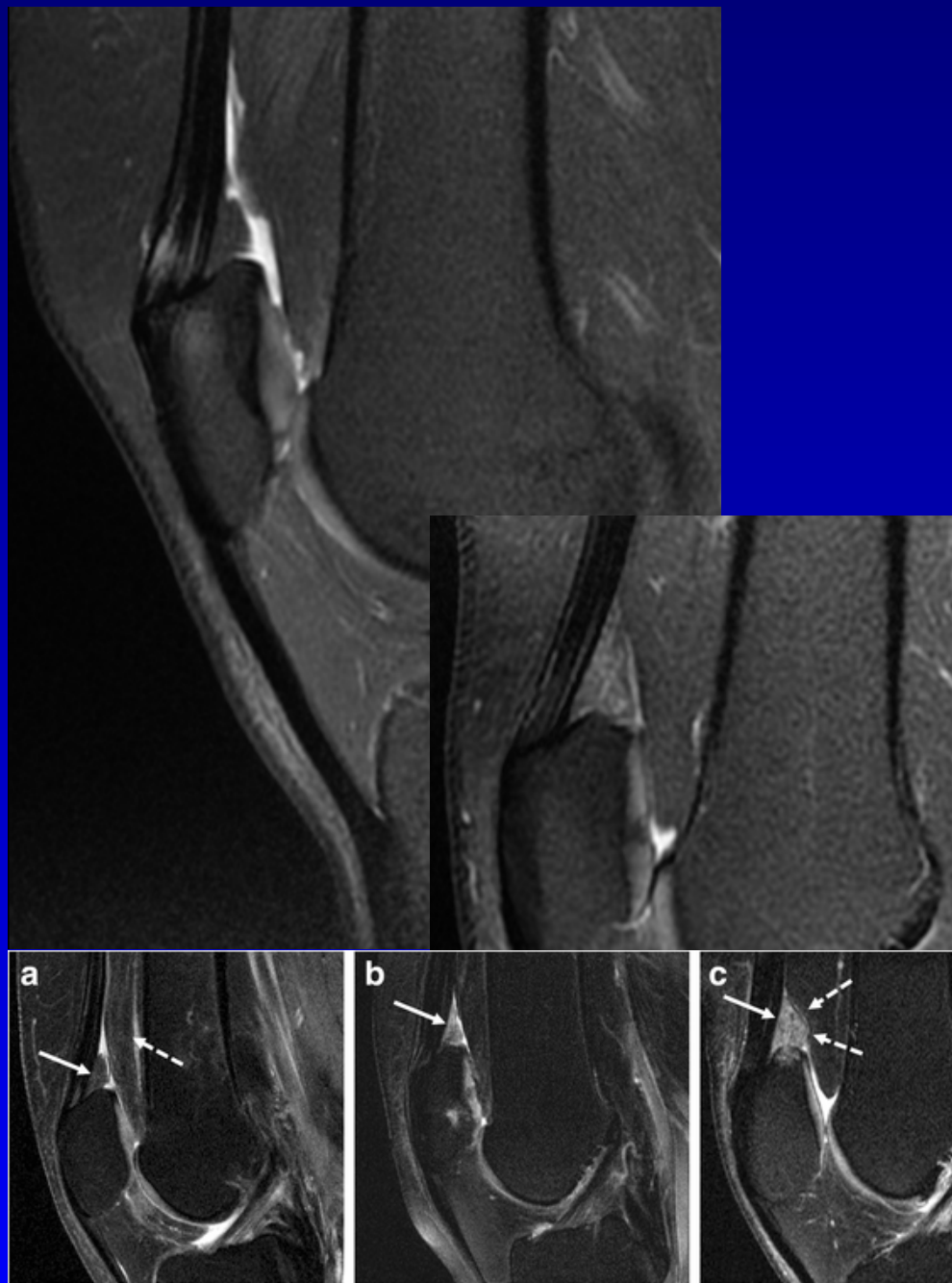
Trochlea N/flat <3mm

grop dybde/brusk

Quadriceps sene og Q. fettpute N/tendinopati/
ruptur/enthesopati

Ligamentum patellae N/tendinopati/
ruptur/enthesopati

Hoffas fettpute N/ødem/ruptur



Fremre kammer / patellofemorale ledd

Patella Posisjon

- vertikal baja/ N 1.1 / alta > 1.3
- aksial lat/med/sub/luksert

Størrelse liten/N/magna

Form Wiberg type 1/2/3

Retropatelær brusk Outerbridge

lett uregelm. signal. N tykkelse 1

moderat <50% 2

markert >50% 3

blottlagt blottlagt ben 4

Trochlea N/flat <3mm

grop dybde/brusk

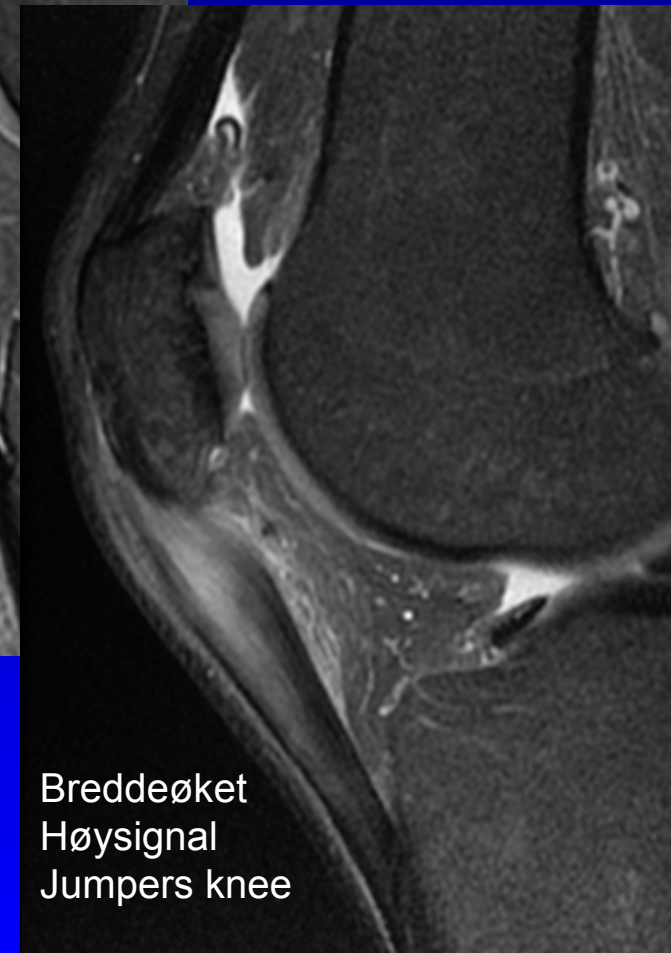
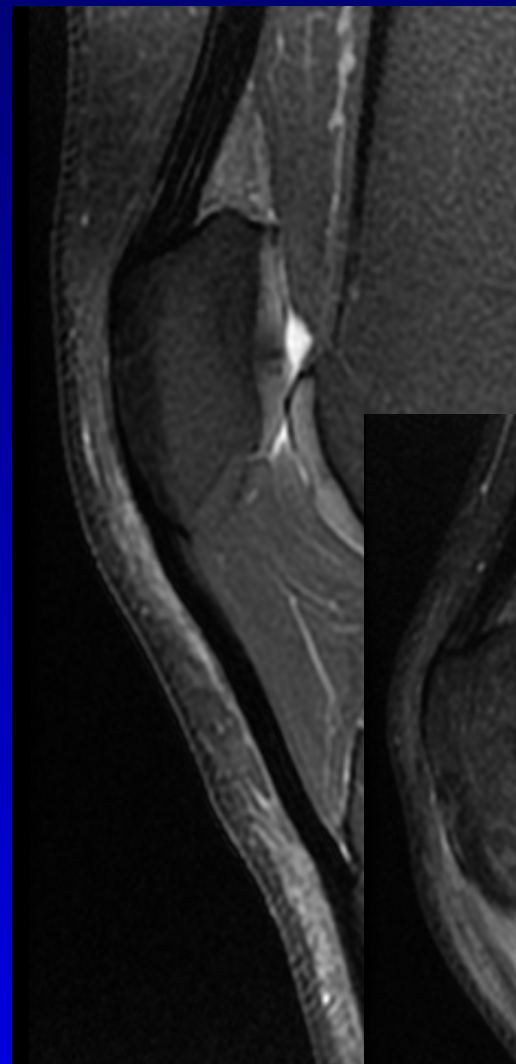
Quadriceps sene N/tendinopati/

og Q. fettpute ruptur/enthesopati

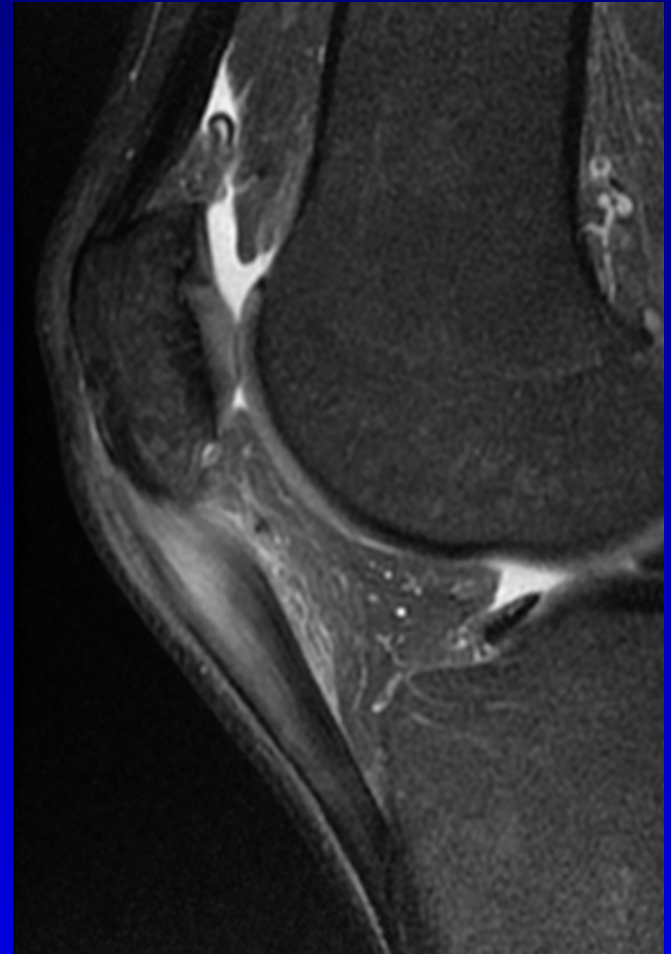
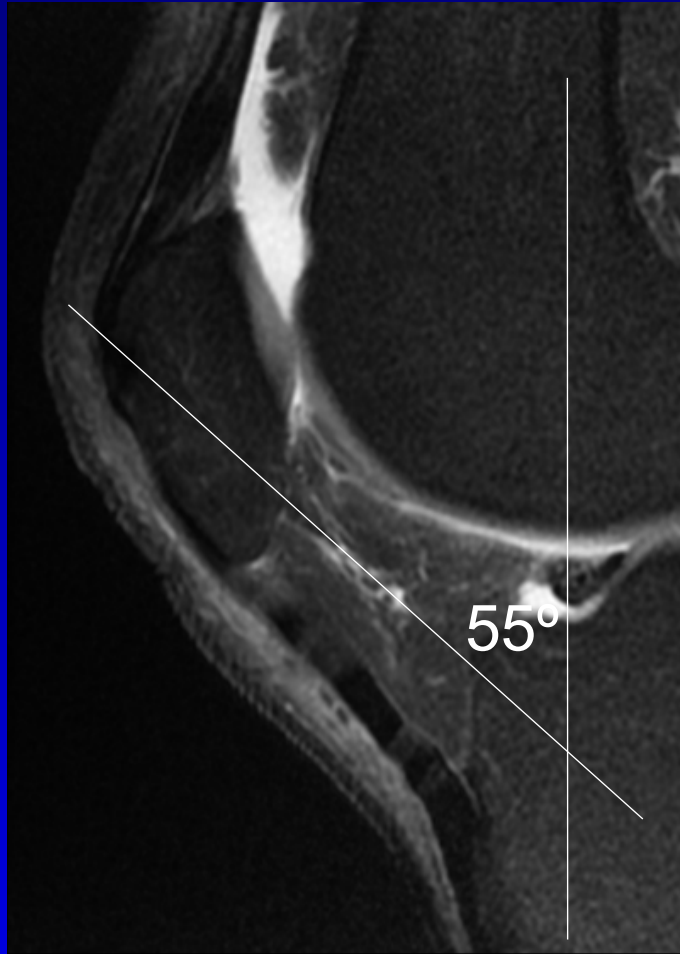

Ligamentum patellae N/tendinopati/

ruptur/enthesopati

Hoffas fettpute N/ødem/ruptur



Breddeøket
Høysignal
Jumpers knee



Fremre kammer / patellofemorale ledd

Patella Posisjon

- vertikal baja/ N 1.1 / alta > 1.3
- aksial lat/med/sub/luksert

Størrelse liten/N/magna

Form Wiberg type 1/2/3

Retropatelær brusk Outerbridge

lett uregelm. signal. N tykkelse 1

moderat <50% 2

markert >50% 3

blottlagt blottlagt ben 4

Trochlea N/flat <3mm

grop dybde/brusk

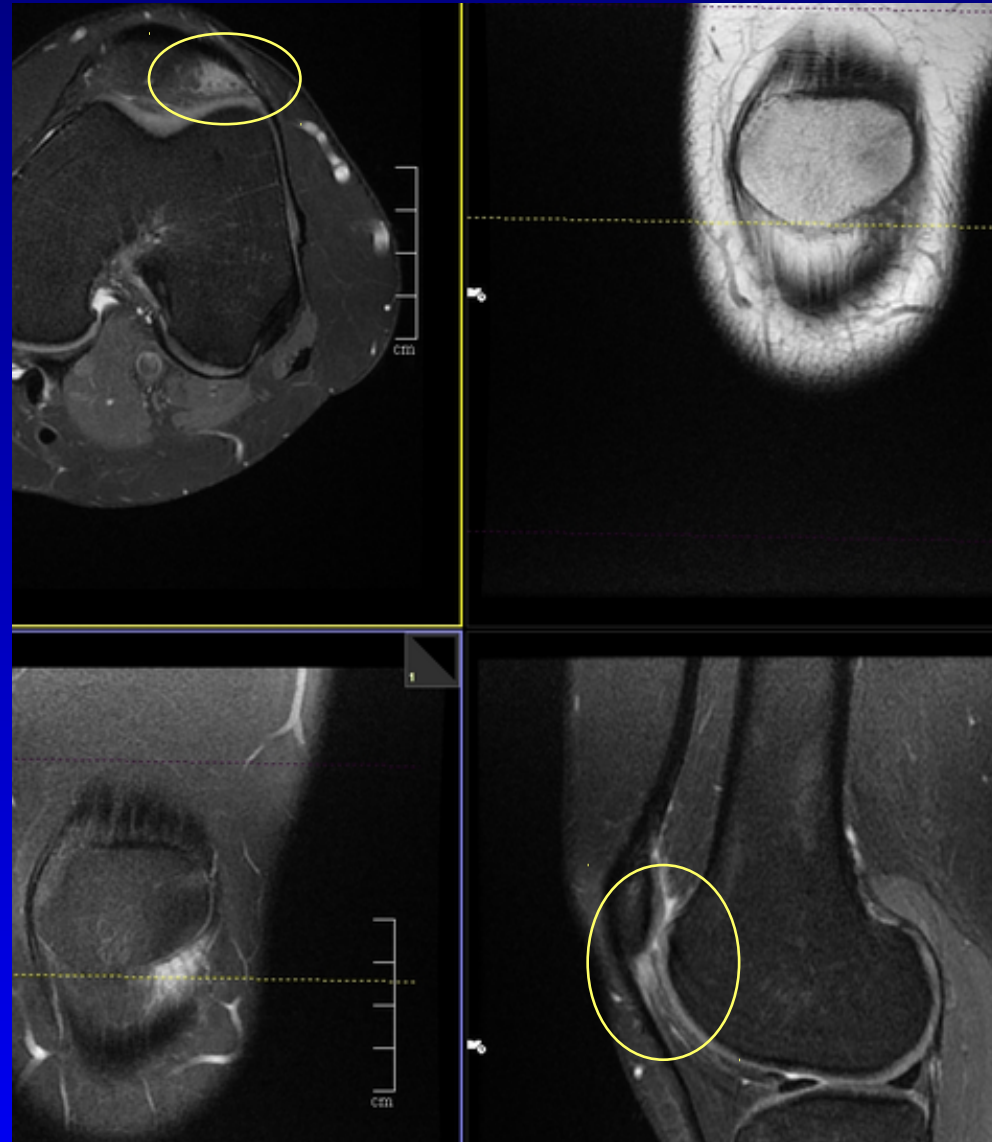
Quadriceps sene N/tendinopati/

og Q. fettpute ruptur/enthesopati

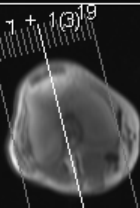
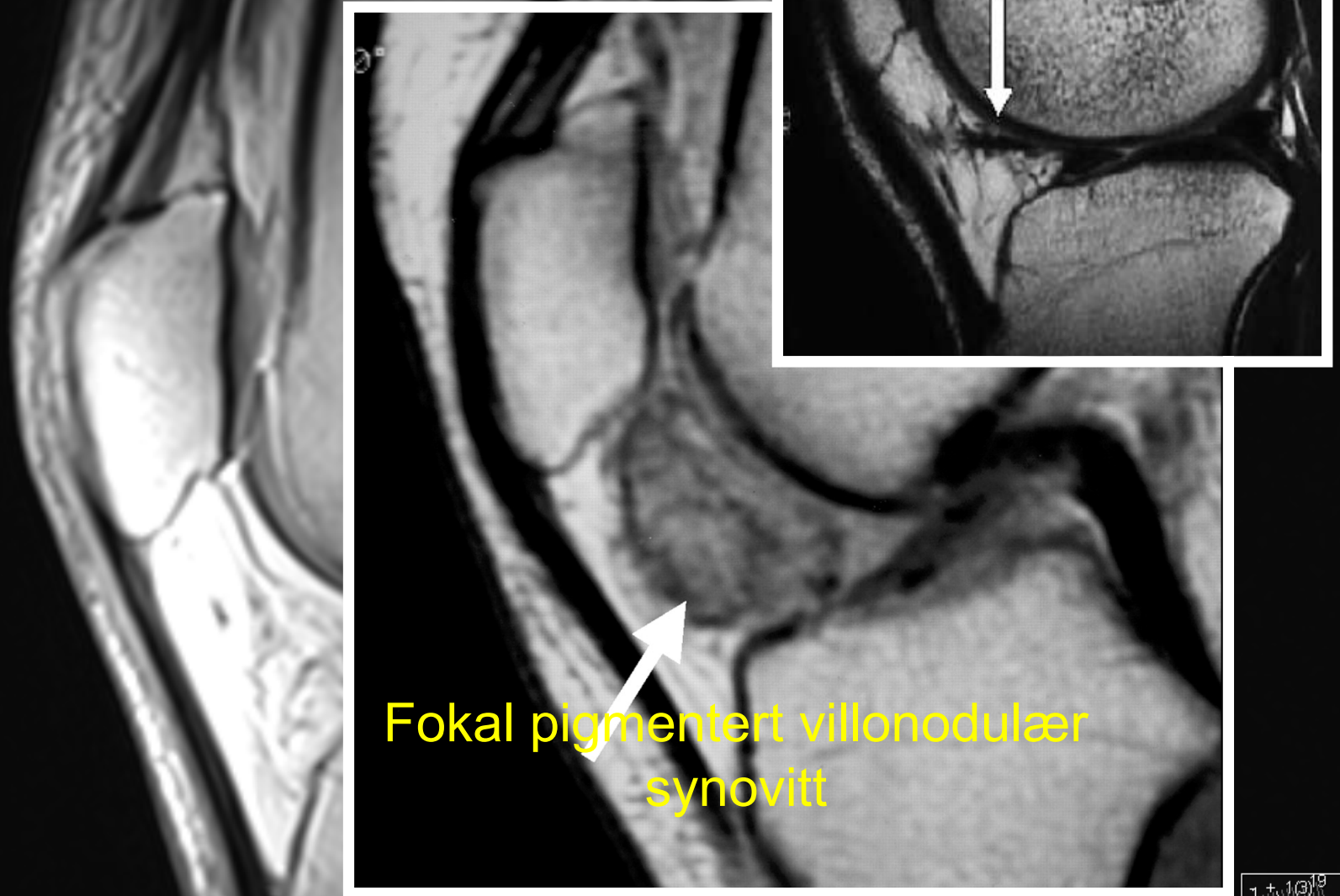
Ligamentum patellae N/tendinopati/

ruptur/enthesopati


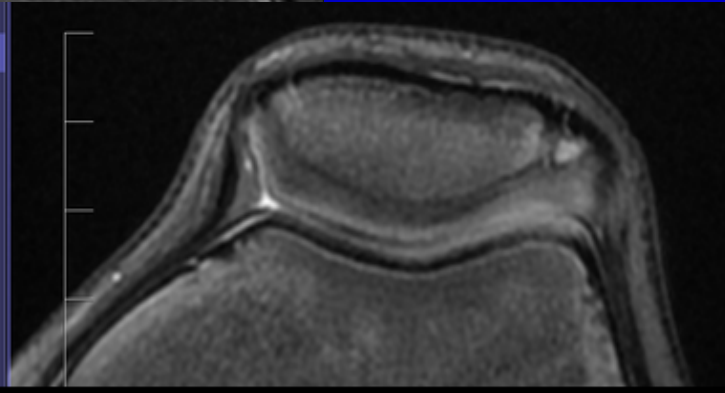
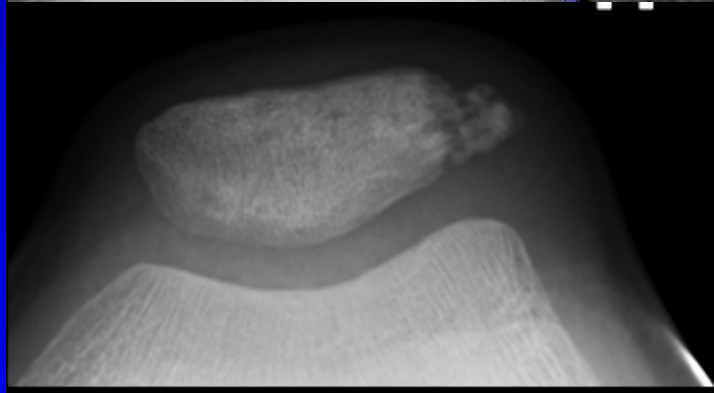
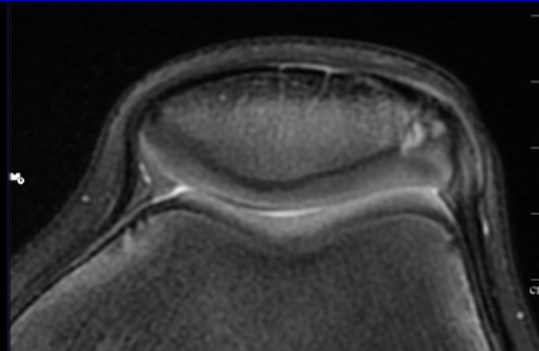
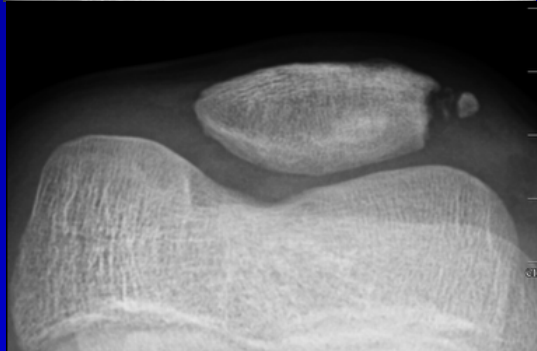
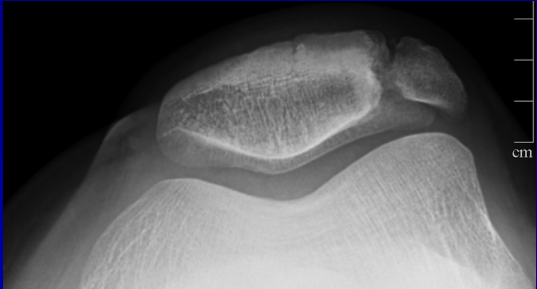
Hoffas fettpute N/ødem/ruptur

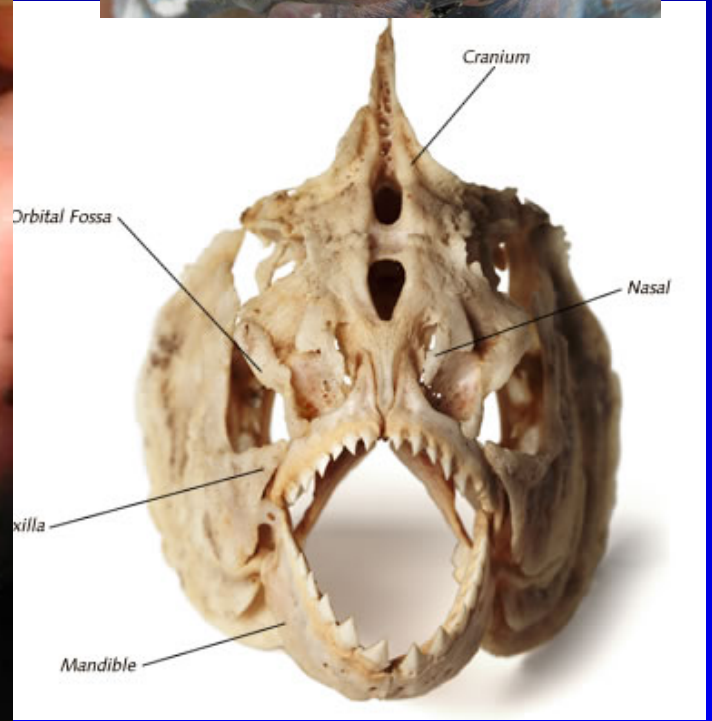
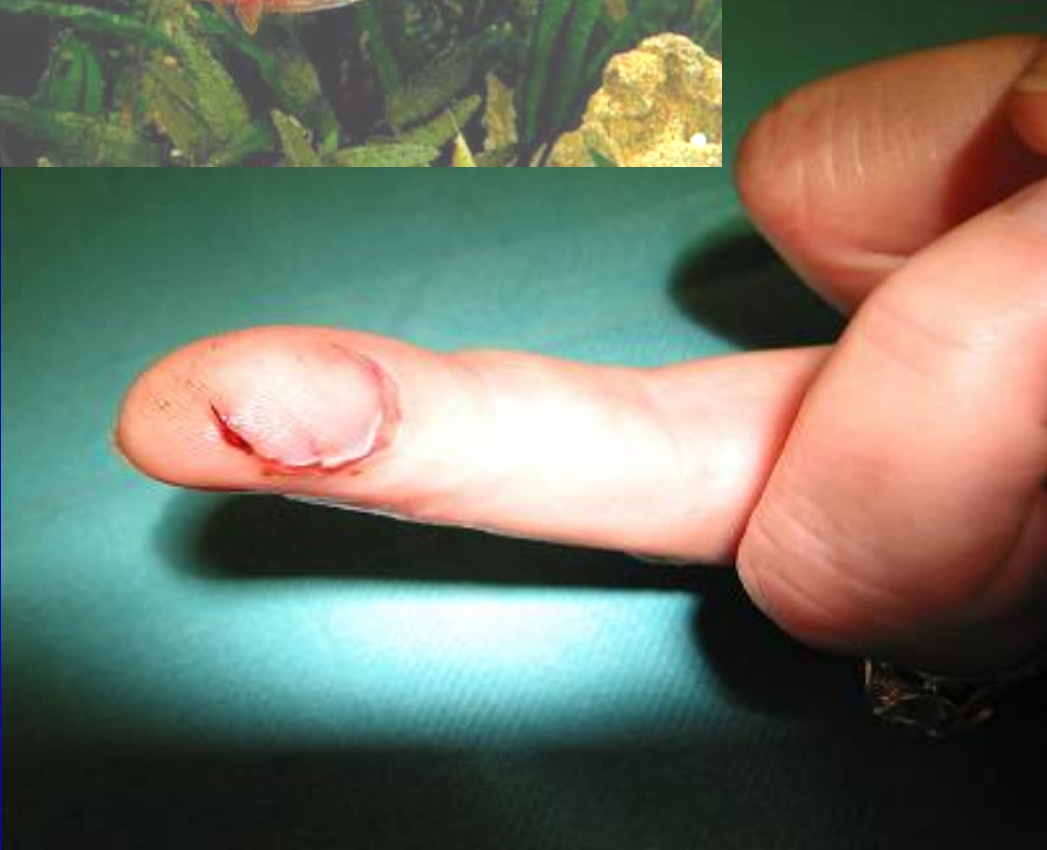

Hoffas fettpute



Normalvariant







NFMSR

NORSK FORENING FOR MUSKEL- OG SKJELETTRADIOLOGI ©

NORWEGIAN MSK IMAGING SEMINAR «LARVIKKURSET»

23-24.04.2020 Farris Bad in Larvik

NORWEGIAN SOCIETY OF MUSCULOSKELETAL
RADIOLOGY

GODKJENT SOM TELLENDE AV LEGEFORENINGEN

KURS ER "FULLY BOOKED"



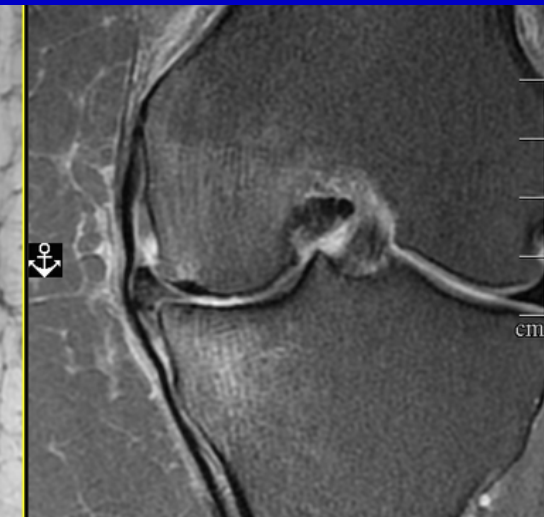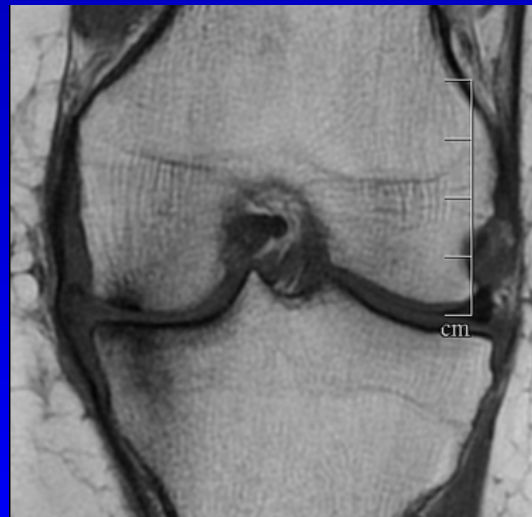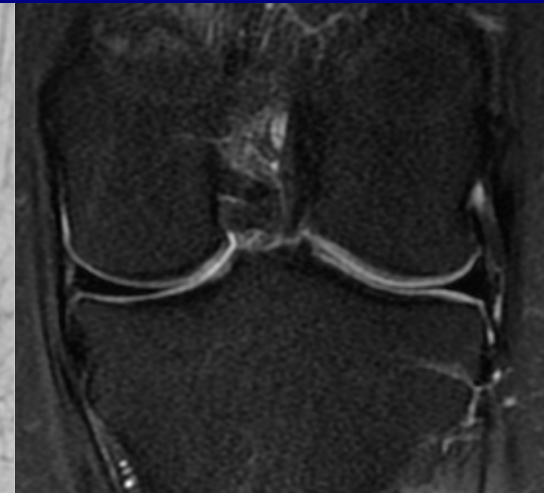
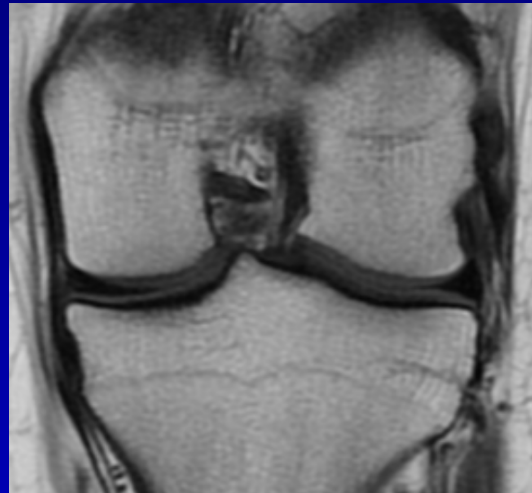Mediale og laterale kammer

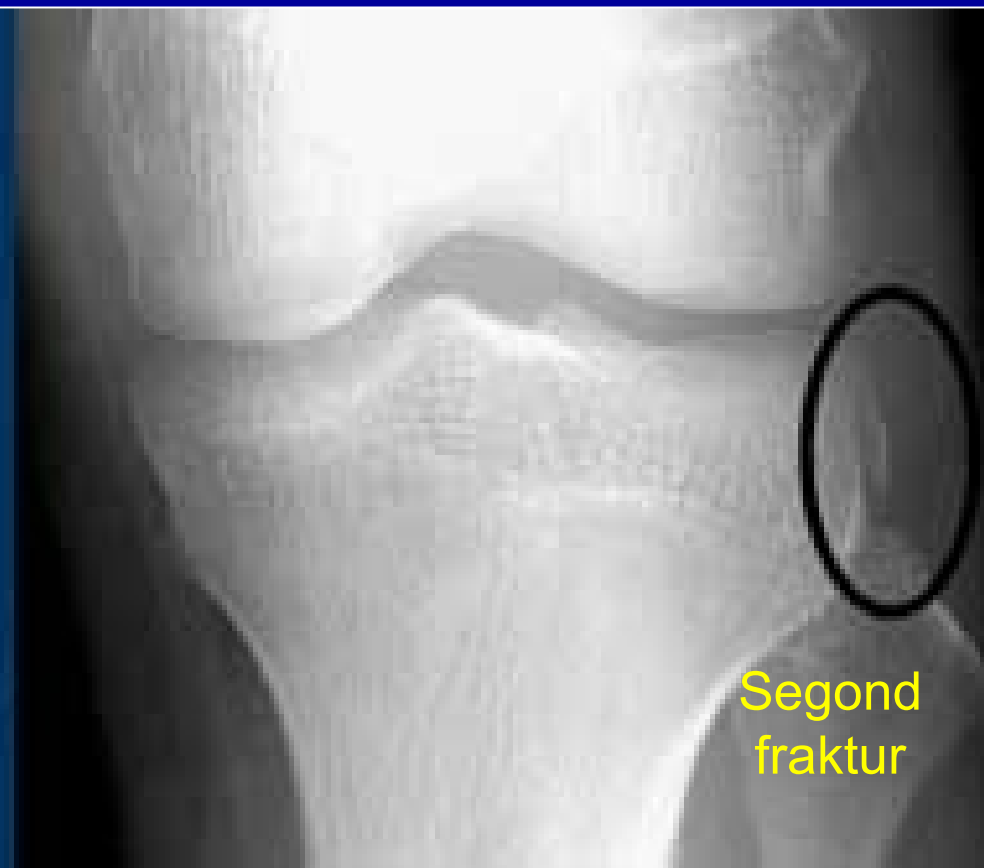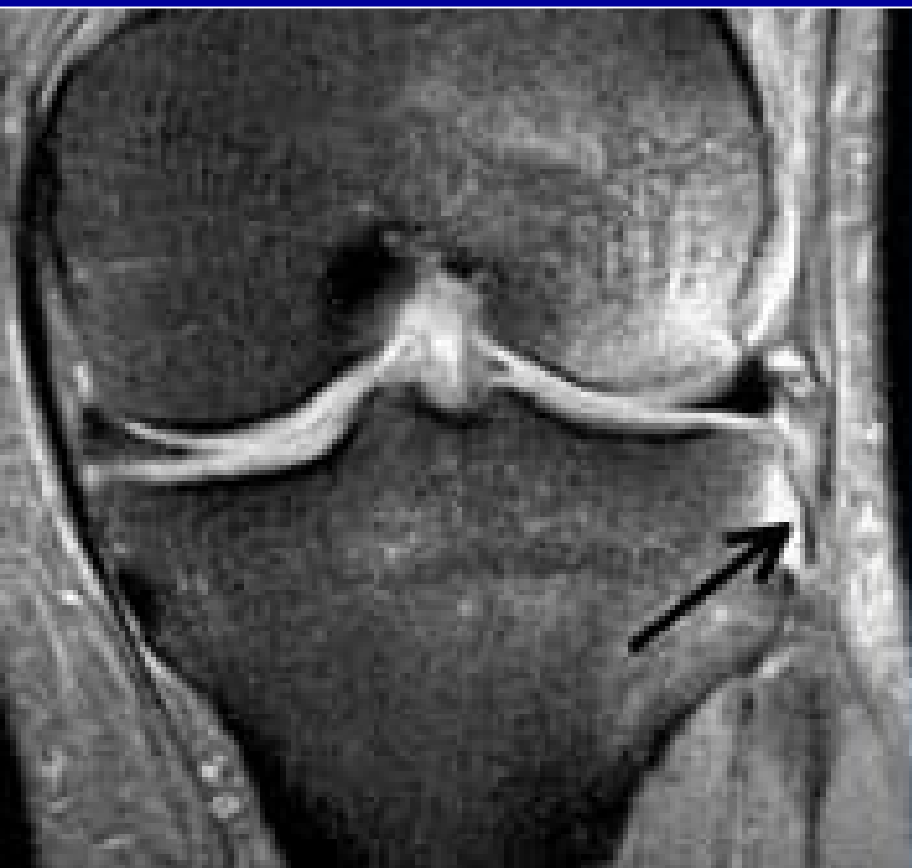Benmarg N/ødem/sklerose/
fokale lesjoner

Leddoverflate jevn/uregelm/
påleiring

Brusk Outerbridge
lett uregelm. signal. N tykkelse 1
moderat <50% 2
markert >50% 3
blottlagt blottlagt ben 4

Menisk høysignal uten ruptur
parameniskial cyste skrått/horisonal
- degenerativ radial/longitudinal
- traumatisk flik/bøttehanke/
Parrot beak
- lokalisering ytre/midtre/inner

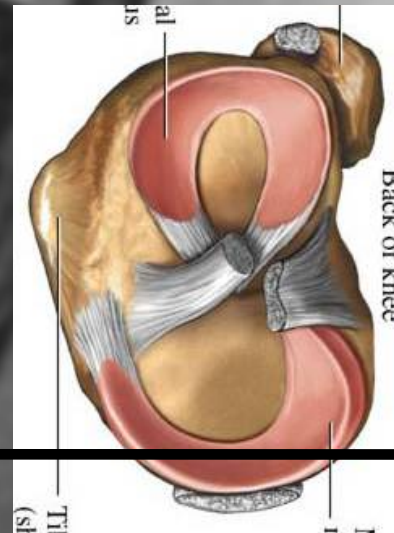





Segond
fraktur



corpus





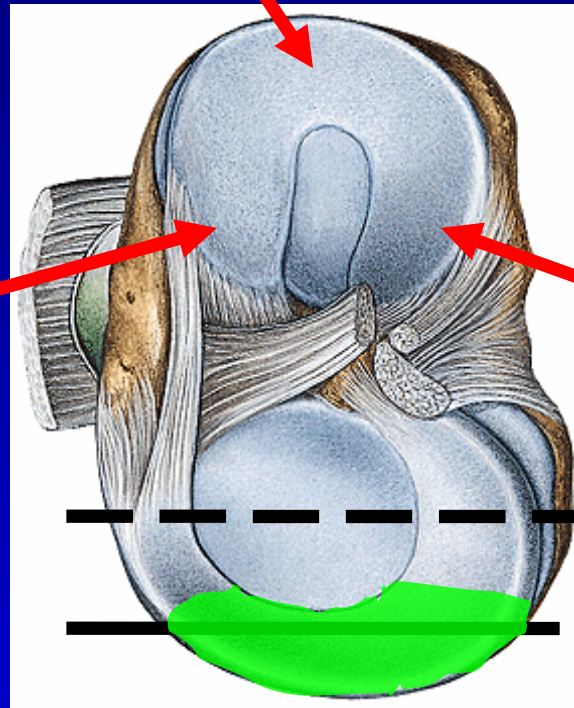
anterior

medial menisk

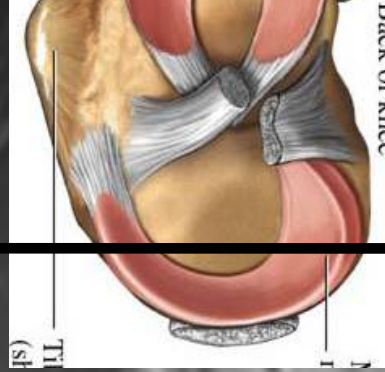
corpus

Anterior horn

Posterior horn

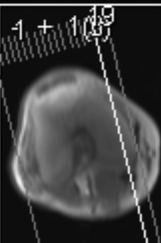
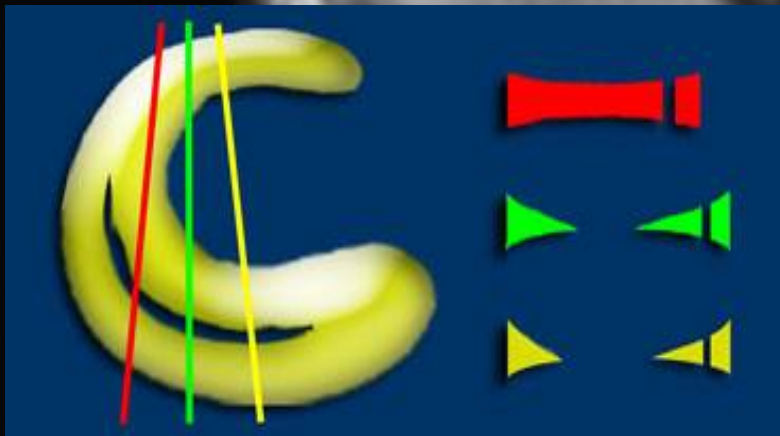


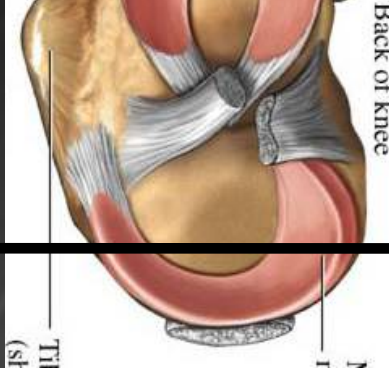
corpus



anterior

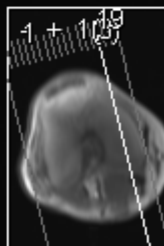
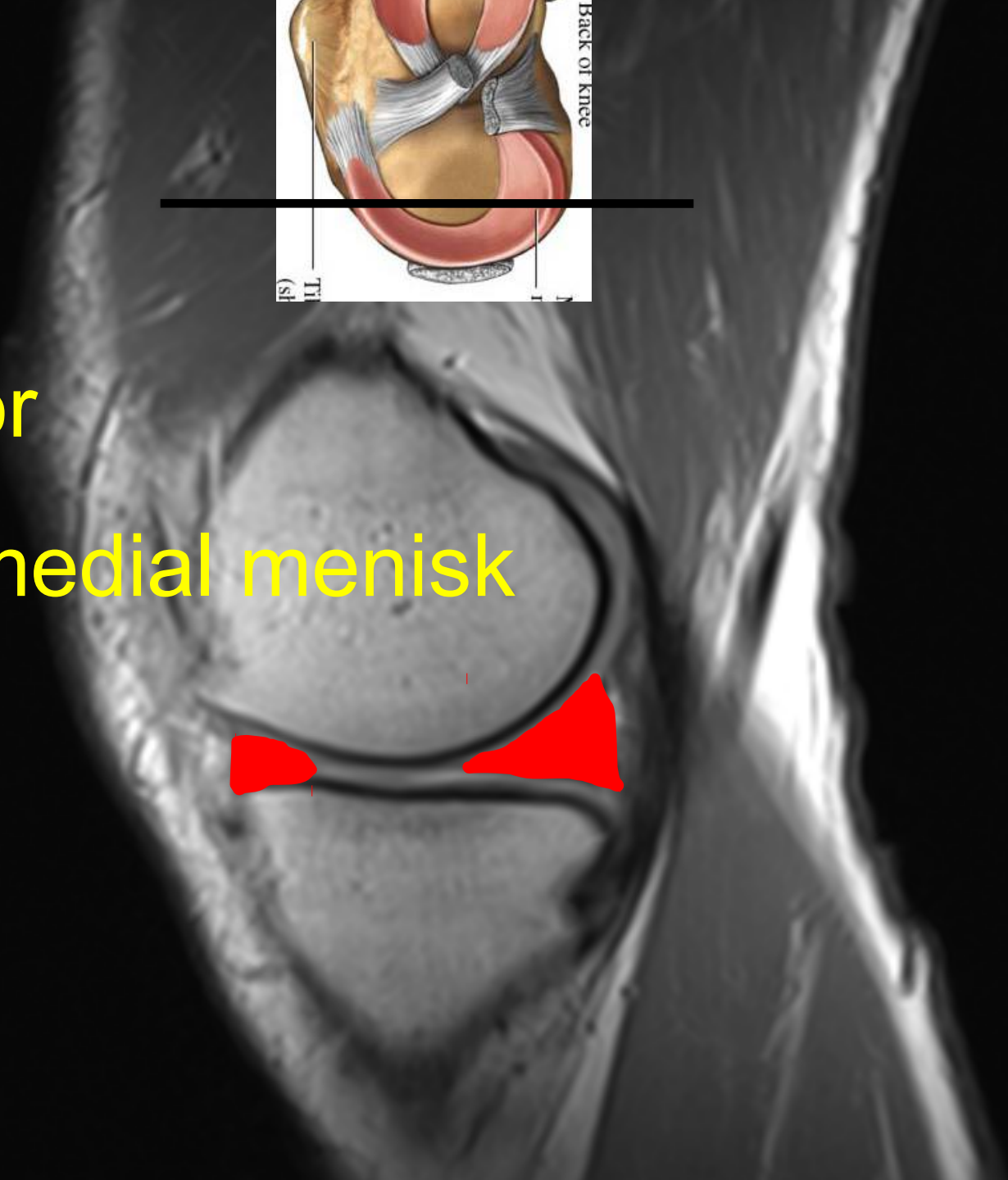
medial menisk

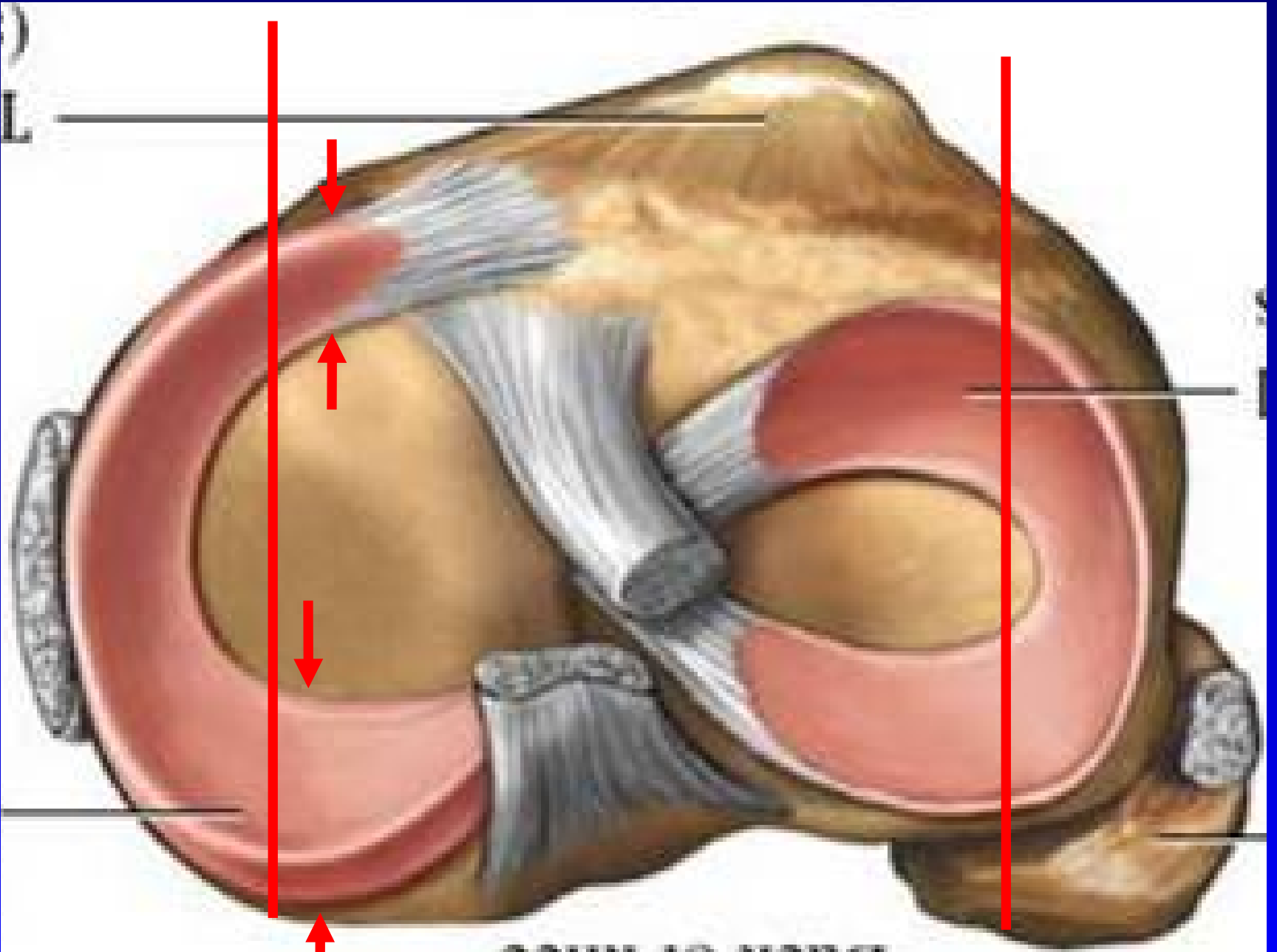




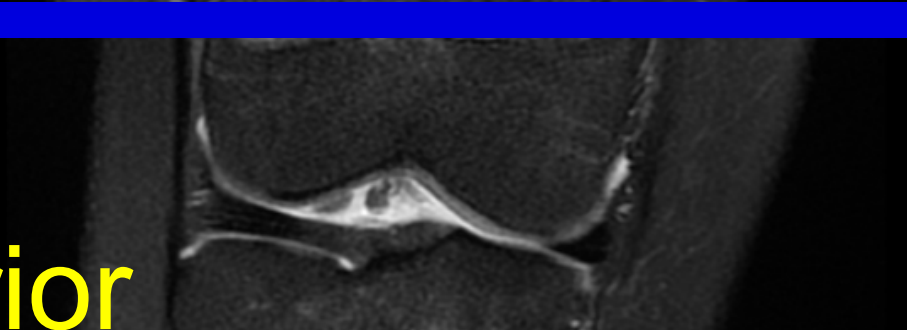
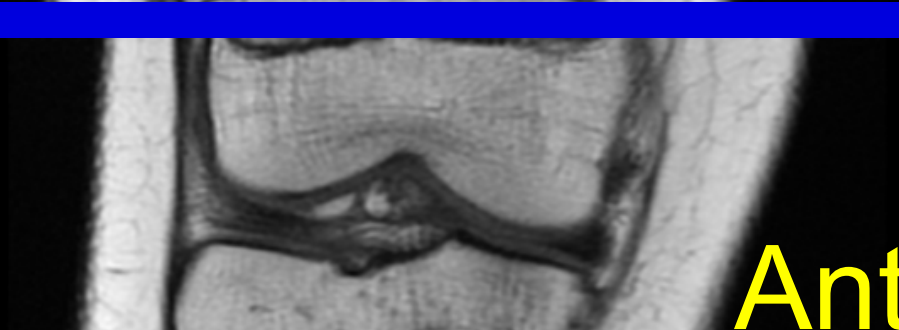
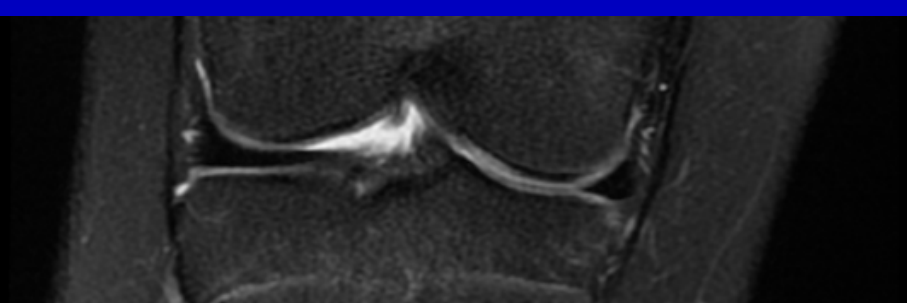
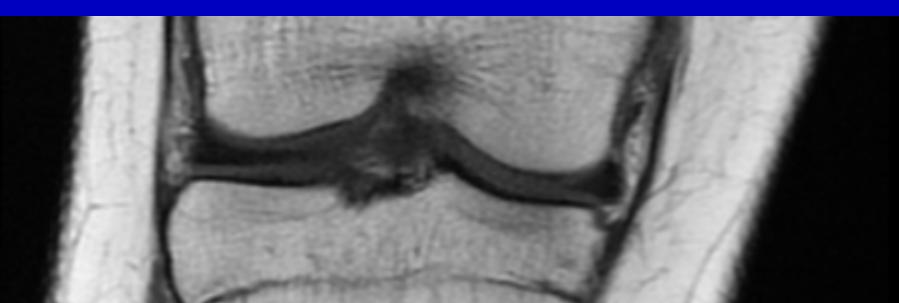
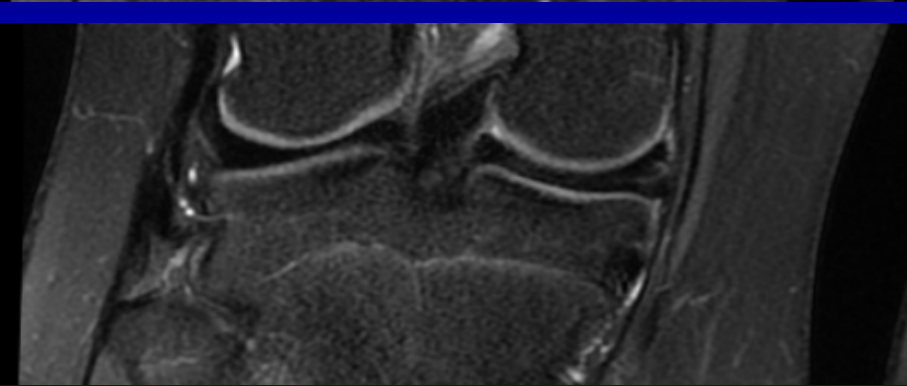
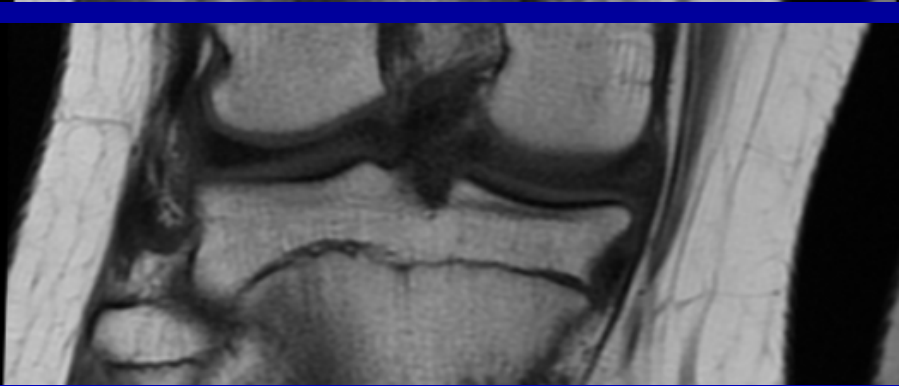
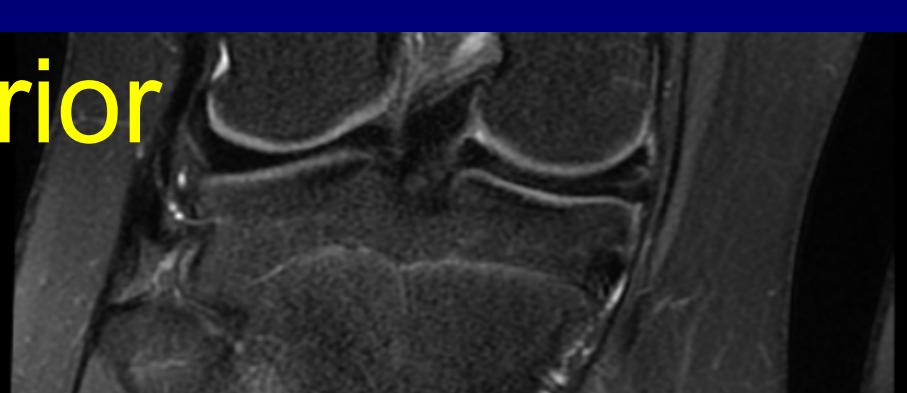
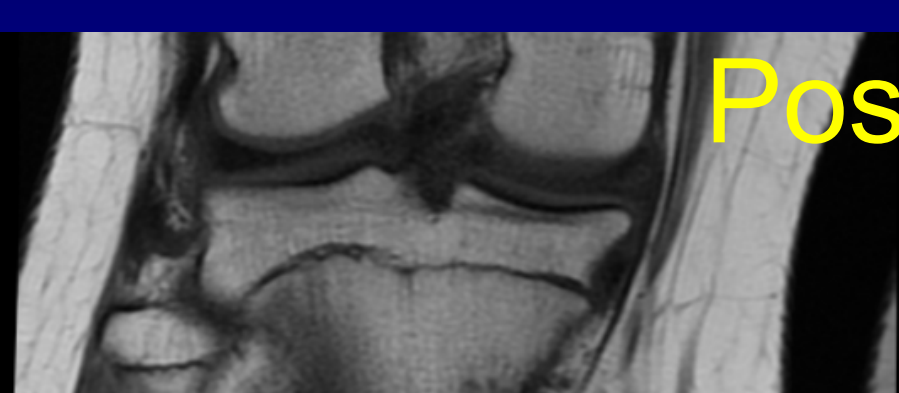
anterior

medial menisk

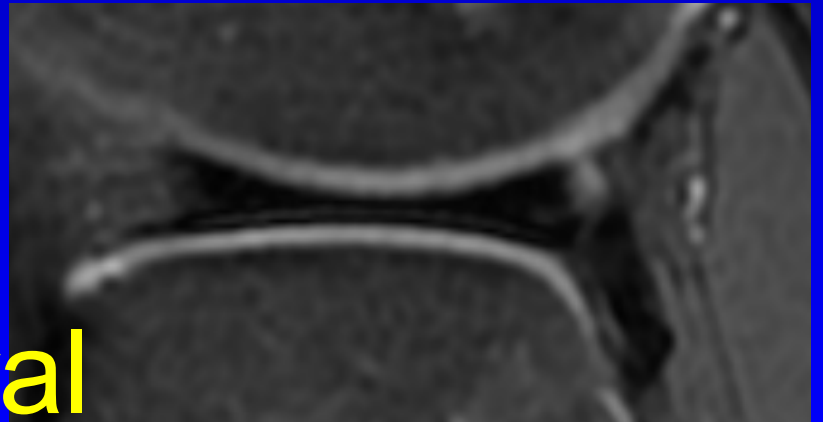
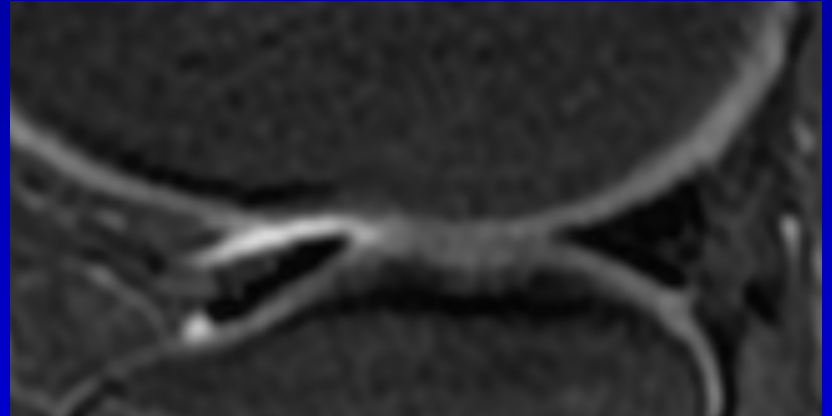
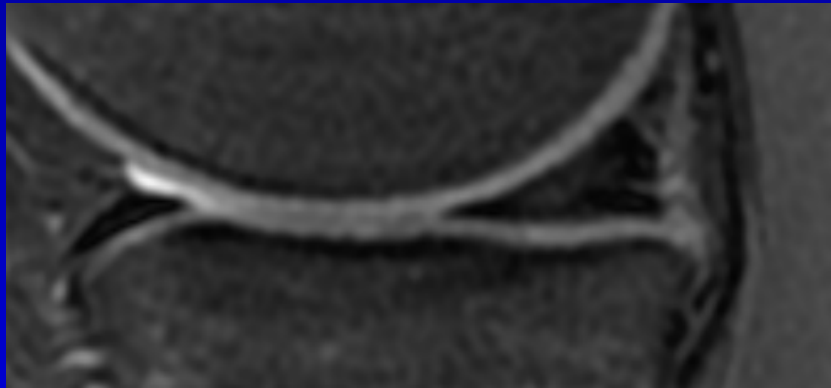
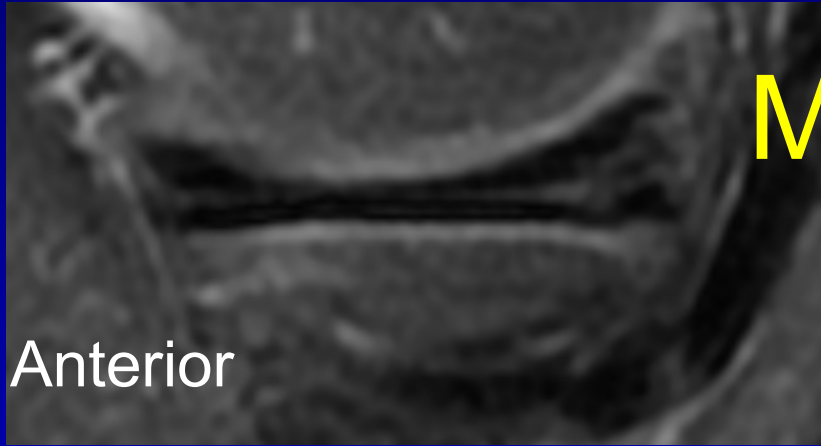




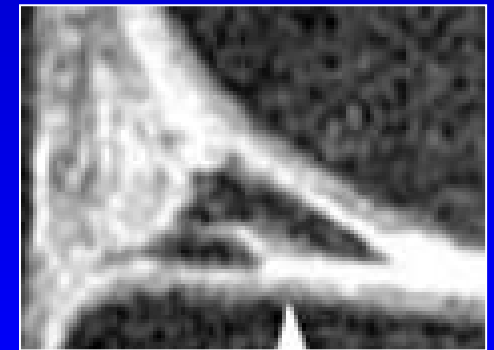

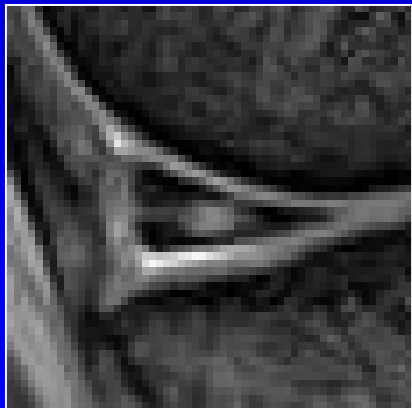
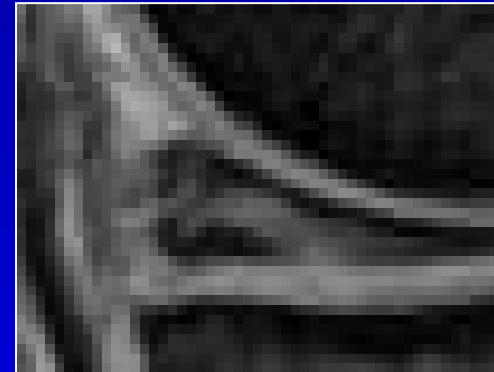
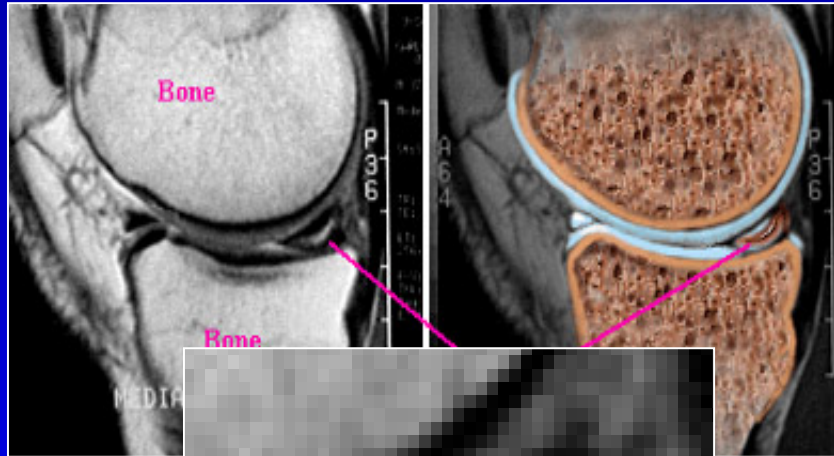
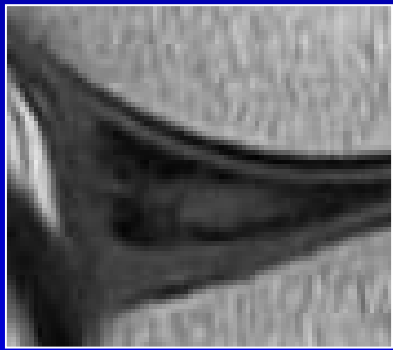



Posterior

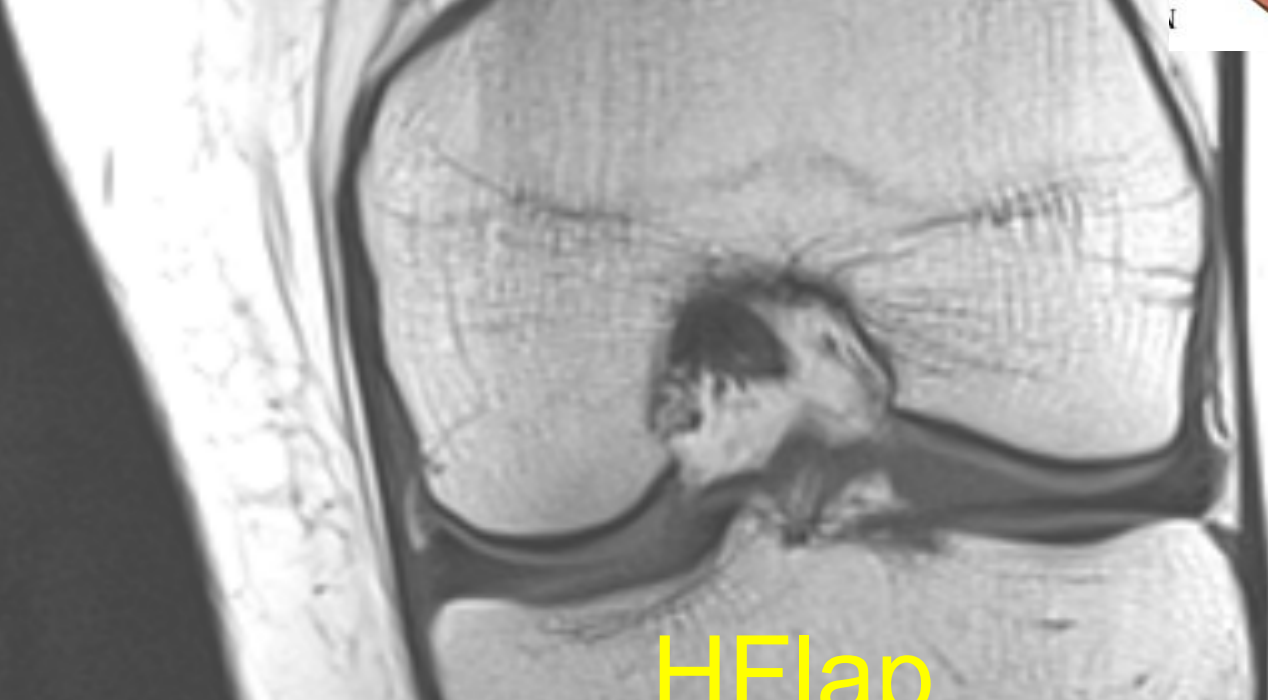
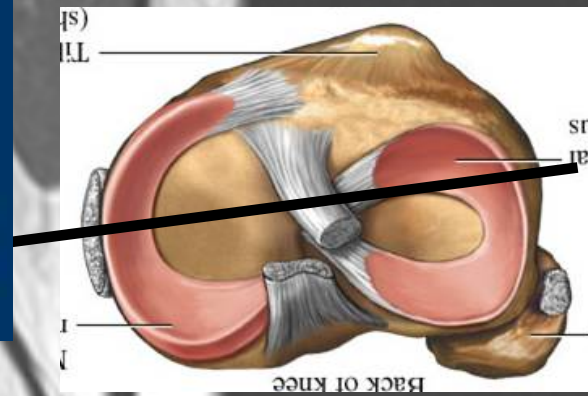


Anterior




Lateral





HFlap

medial



Parrot beak

Ligamenter

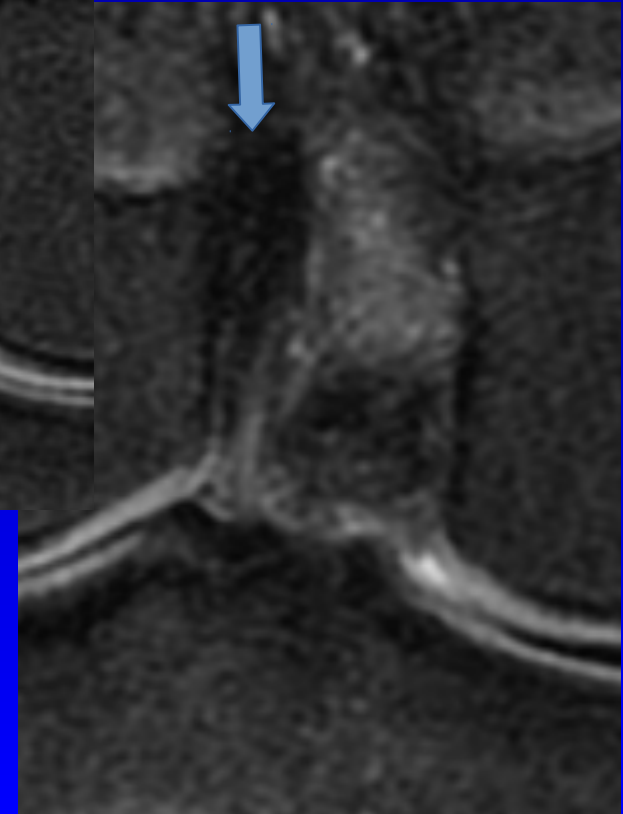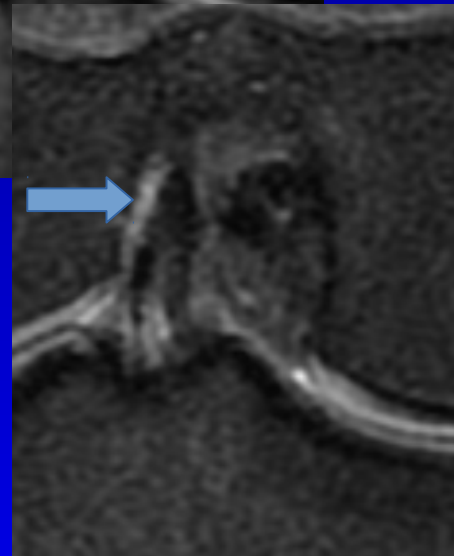
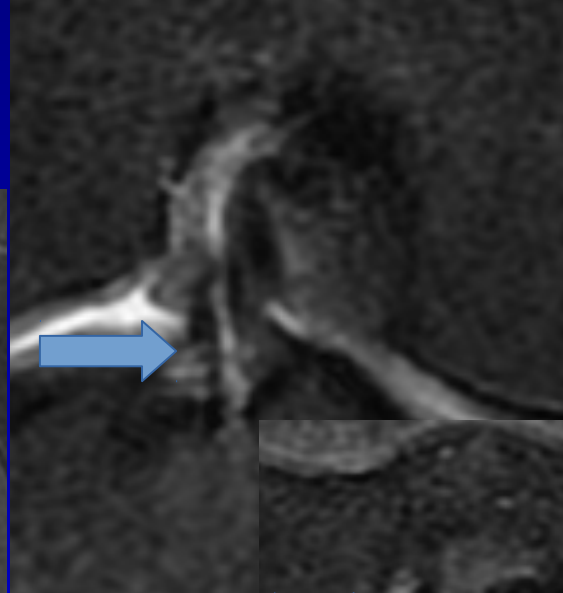
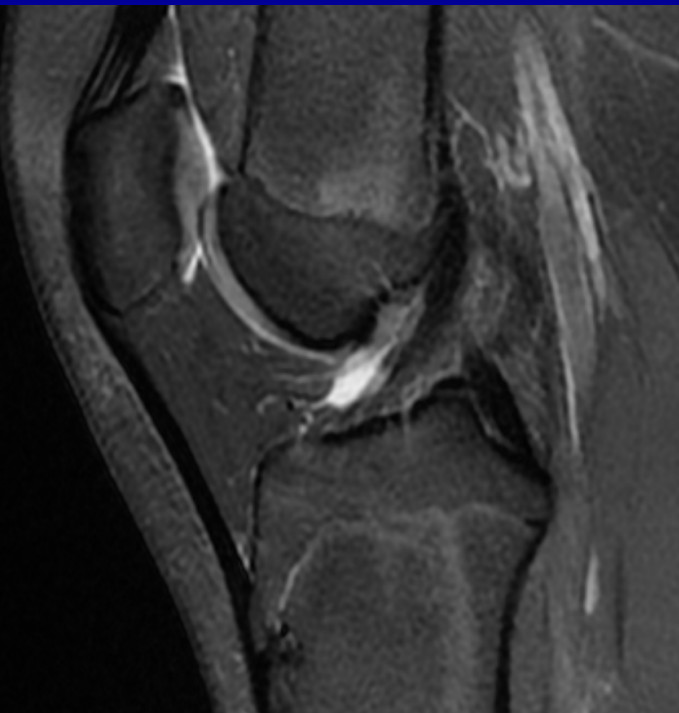Fremre korsbånd ACL N/mucoid degen/
ruptur

Bakre korsbånd PCL N/mucoid degen/
ruptur

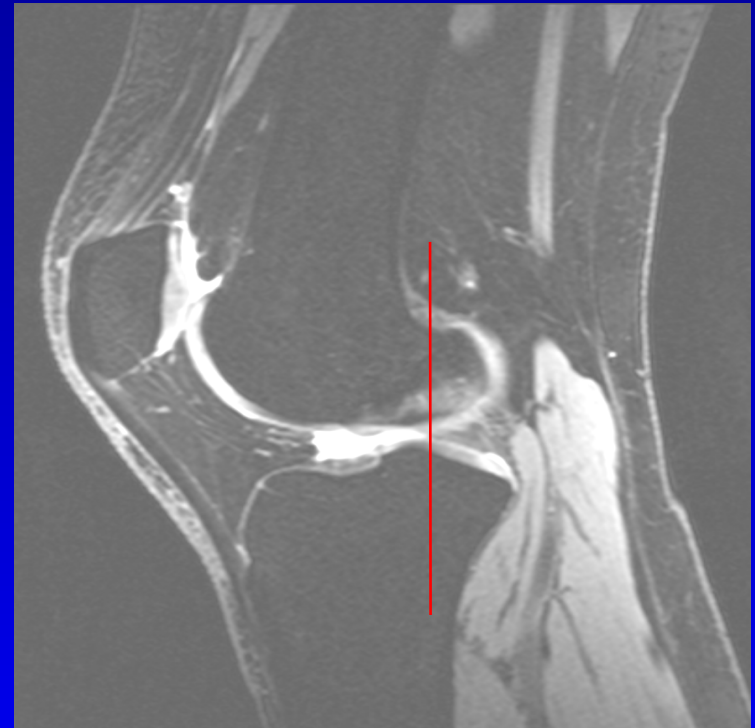
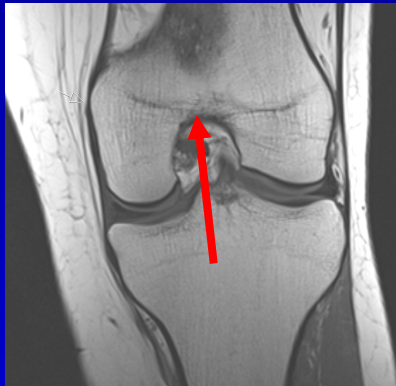Med. kollaterallig MCL N/fortykket/
m-femoral/m-tibial høysignal/ruptur

Lat. kollaterallig LCL N/fortykket/
høysignal/ruptur

ACL Coronale bilder!

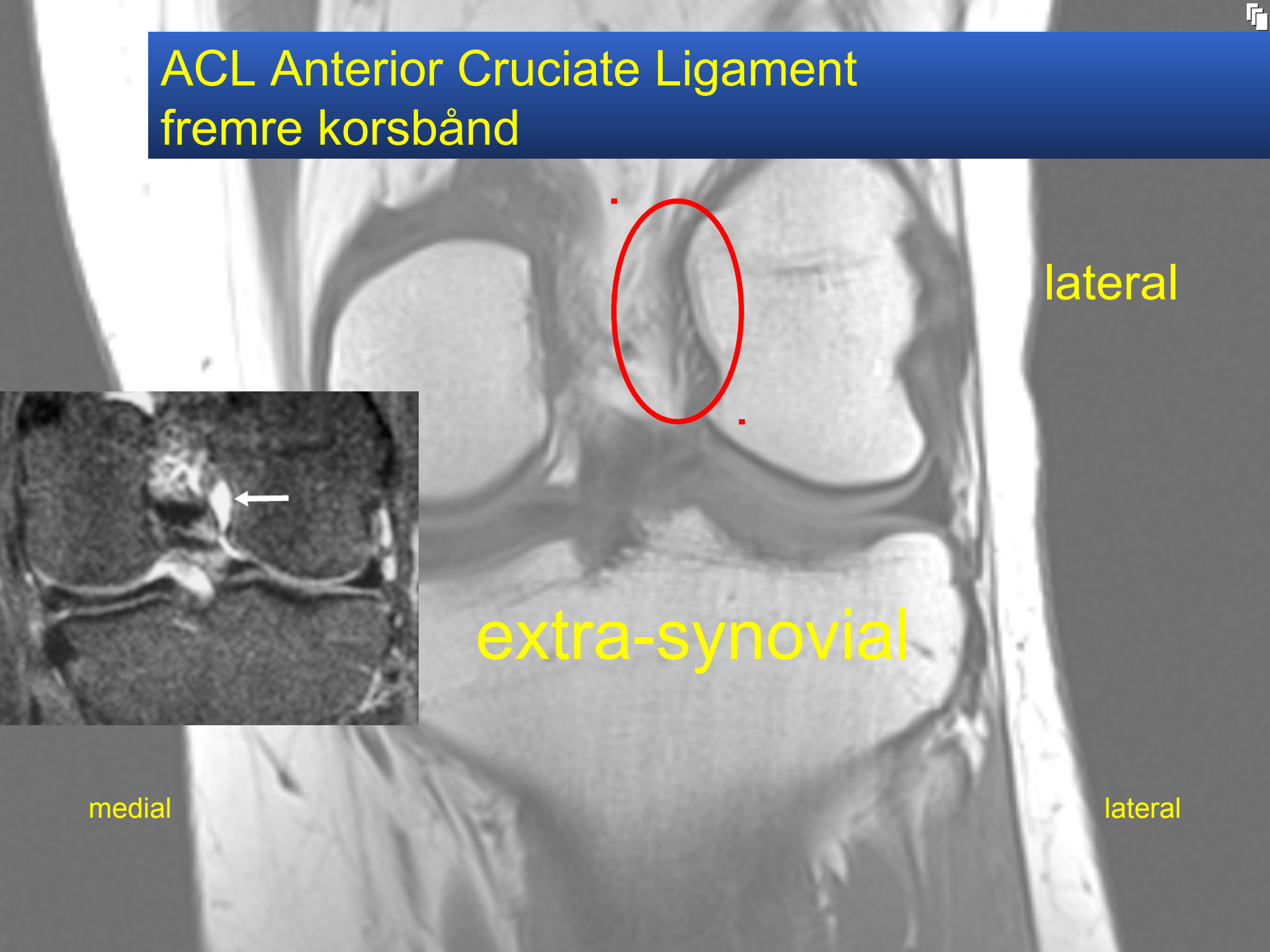


ACL Anterior Cruciate Ligament fremre korsbånd



- Fusjon av femoral kondyler
- 2-3 snitt dorsal

ACL Anterior Cruciate Ligament fremre korsbånd

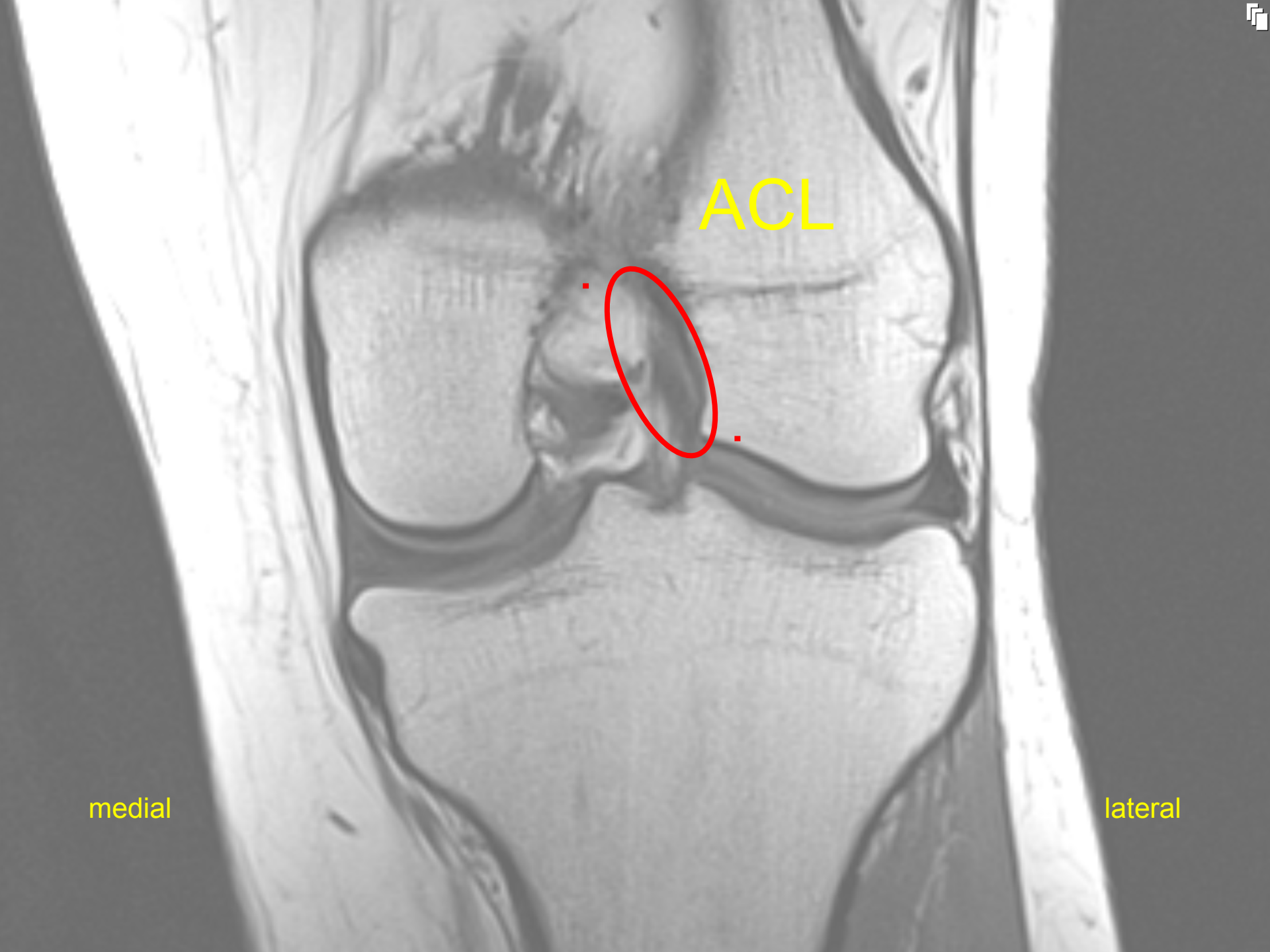

lateral

extra-synovial

medial

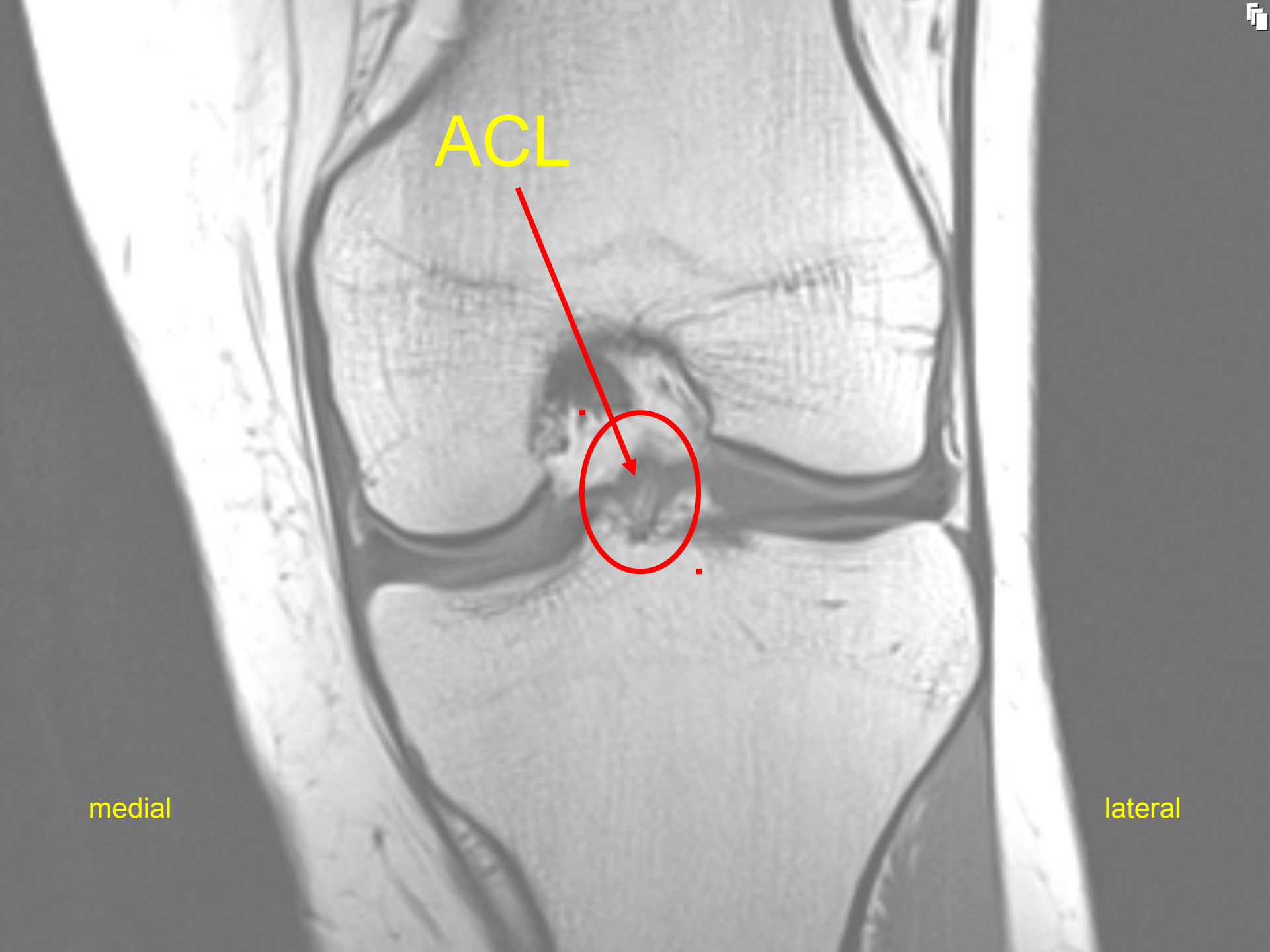
lateral



ACL

medial

lateral



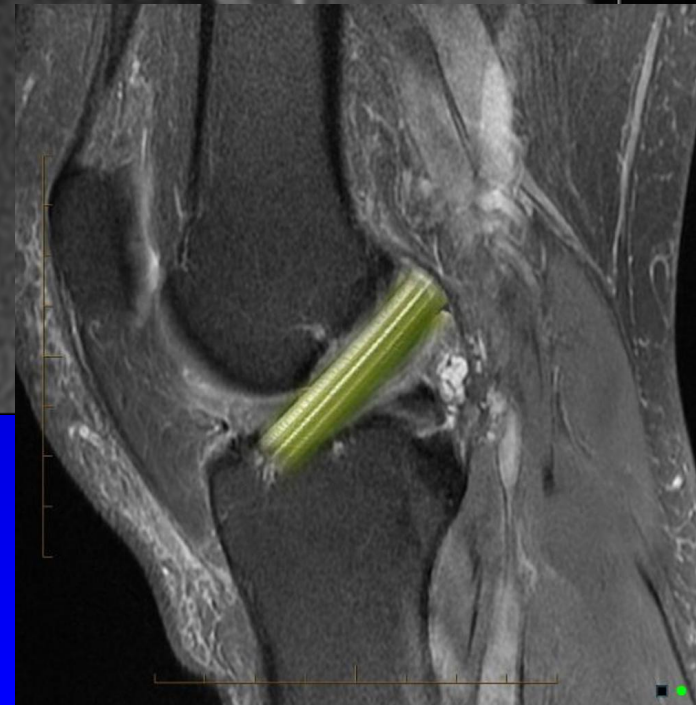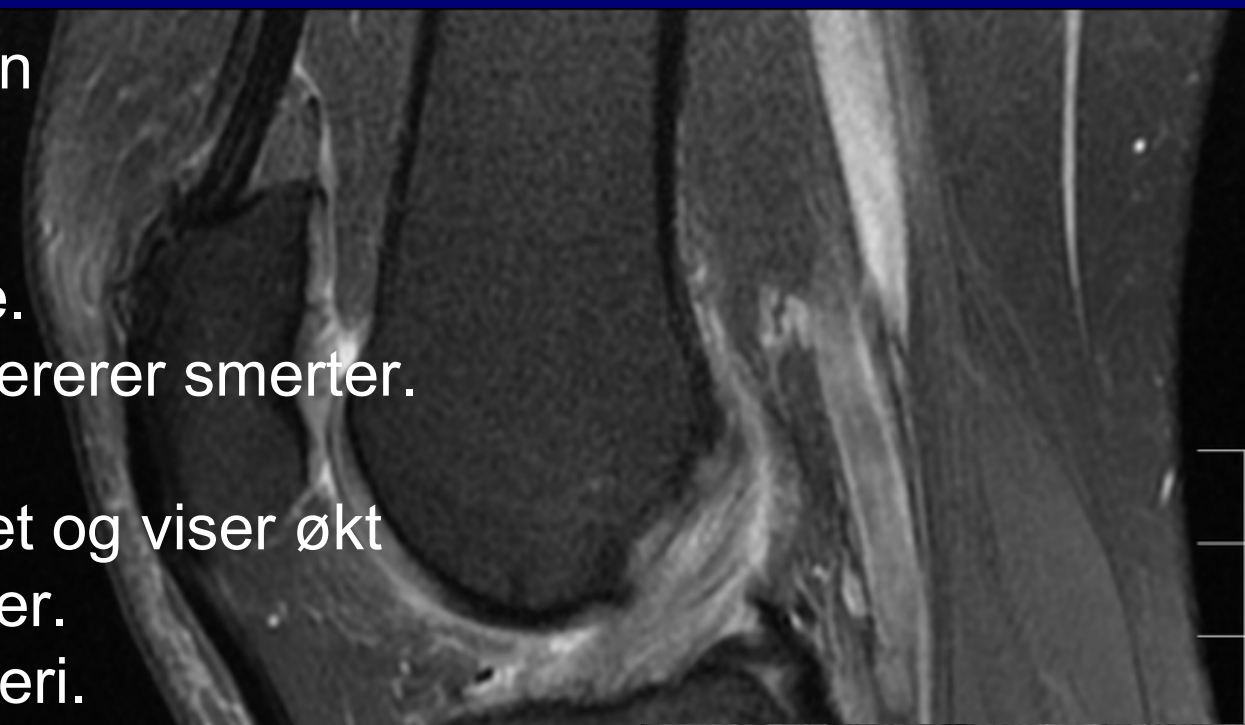
ACL


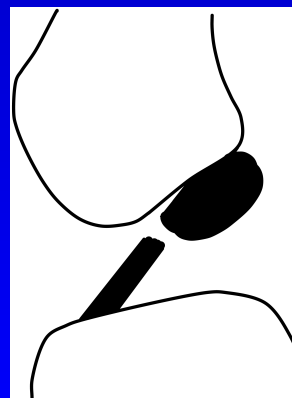
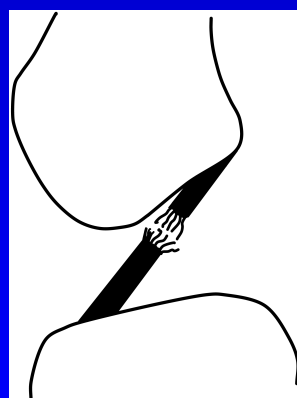
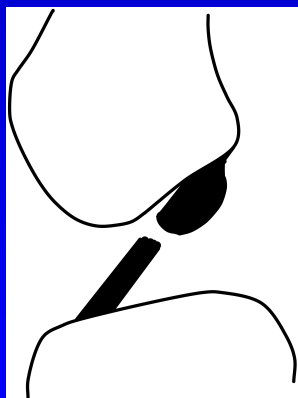
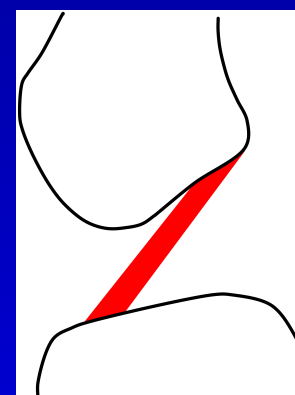
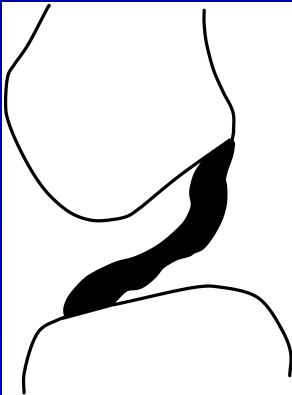
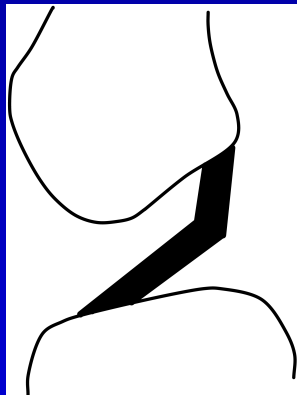
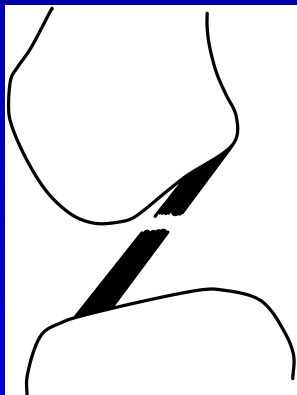

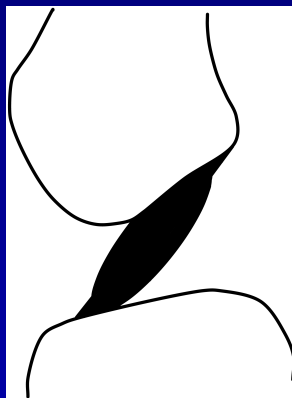


medial

lateral

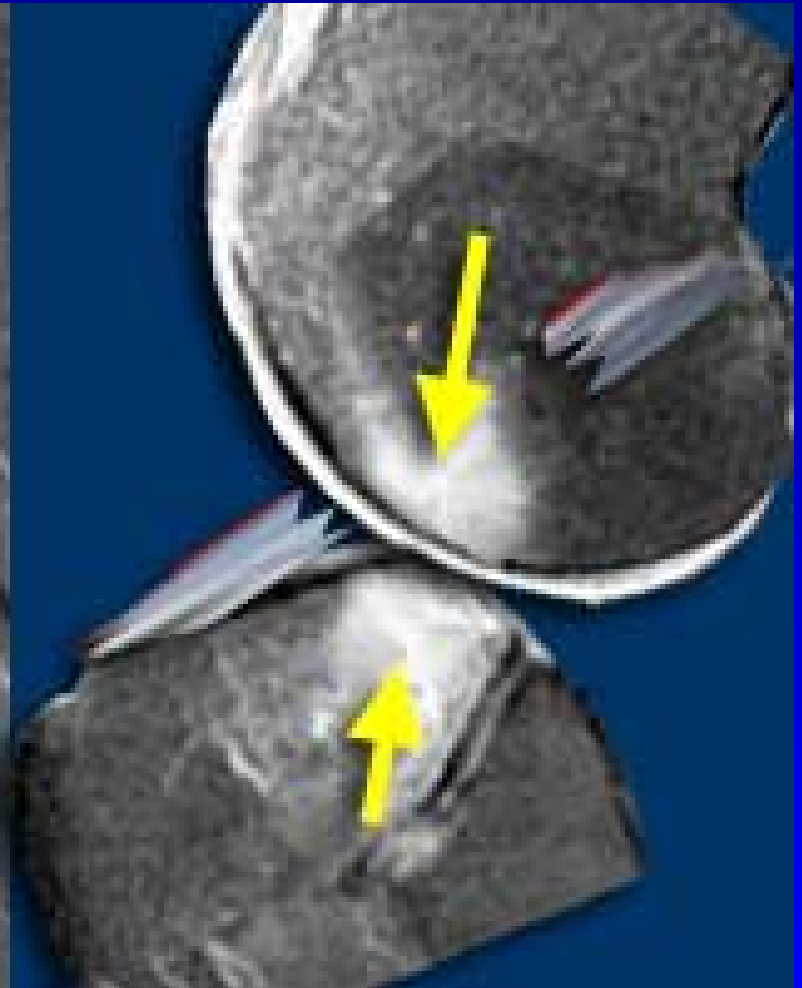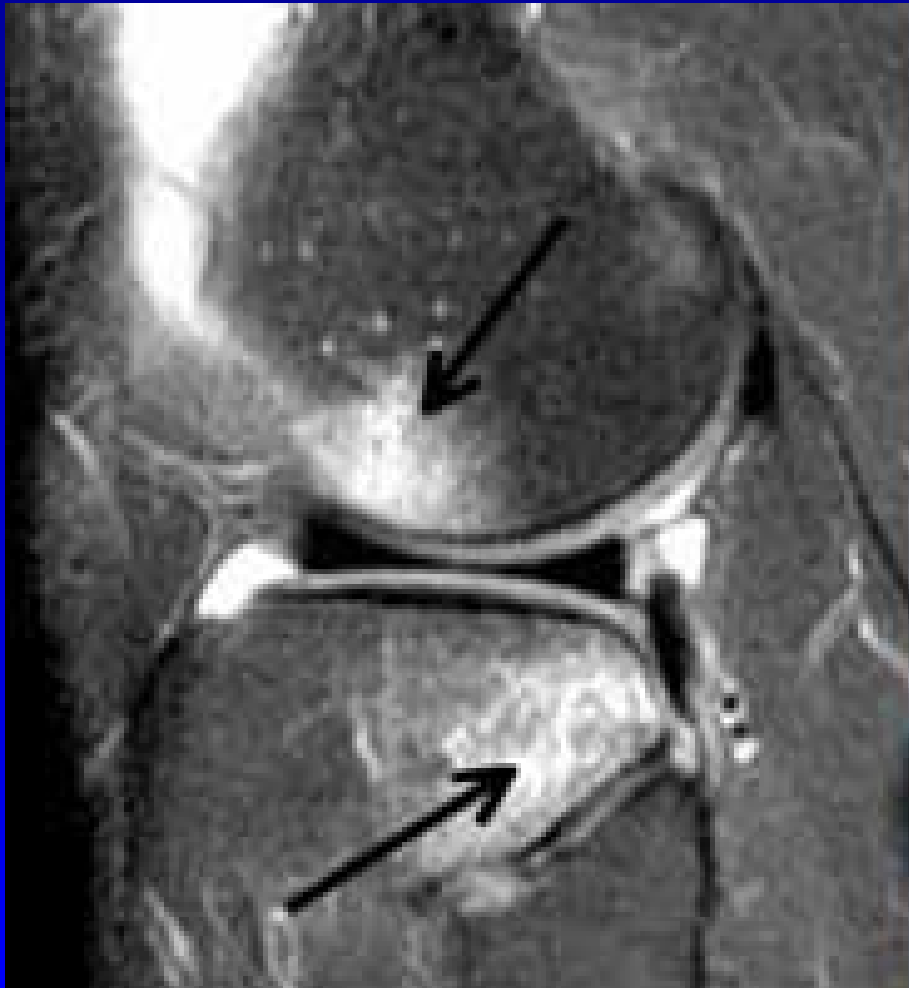Mycoïd degenerasjon

- Oftest i ACL.
 - Usikkert patogenese.
 - Usikkert om det genererer smerter.
 - Oftest tilfeldig funn.
 - Korsbånd er fortykket og viser økt signal i alle sekvenser.
 - Minner om stangselleri.
- Kan se ut som akutt eller kronisk partiell intrasubstans ruptur.
- Ved mucoid degenerasjon mangler klinisk historie og sekundære tegn til ACL ruptur som

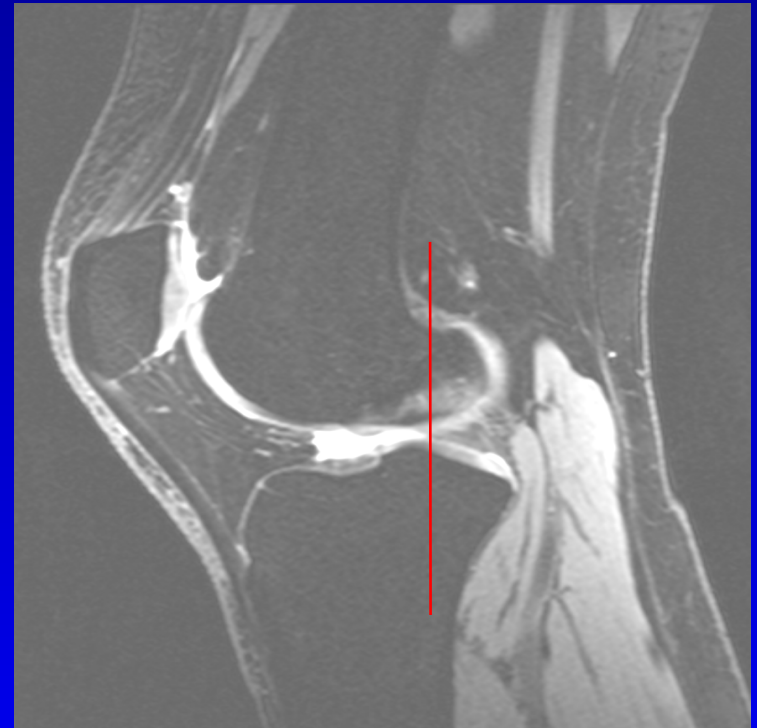


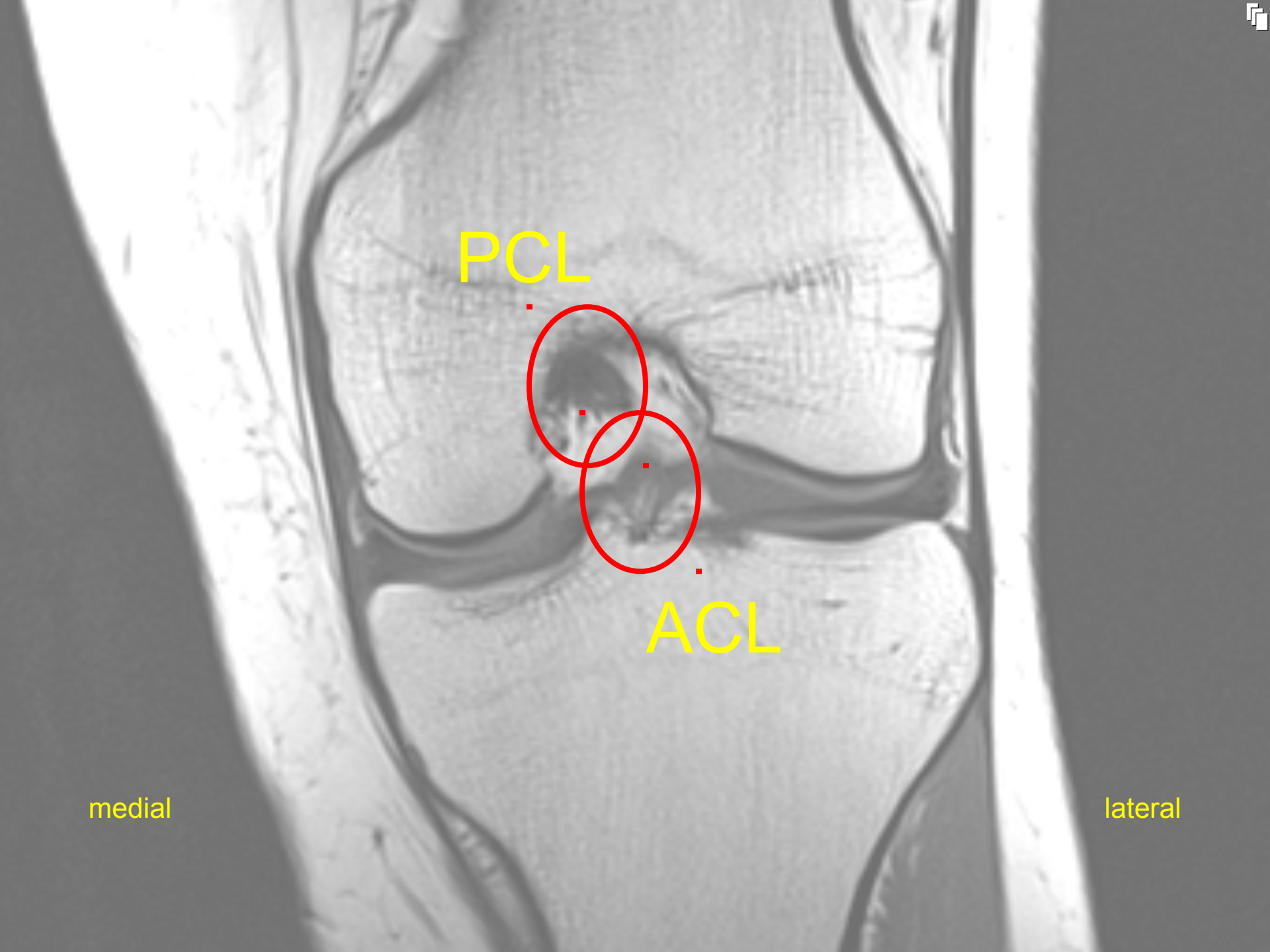


bone bruise



PCL Posterior Cruciate Ligament bakre korsbånd



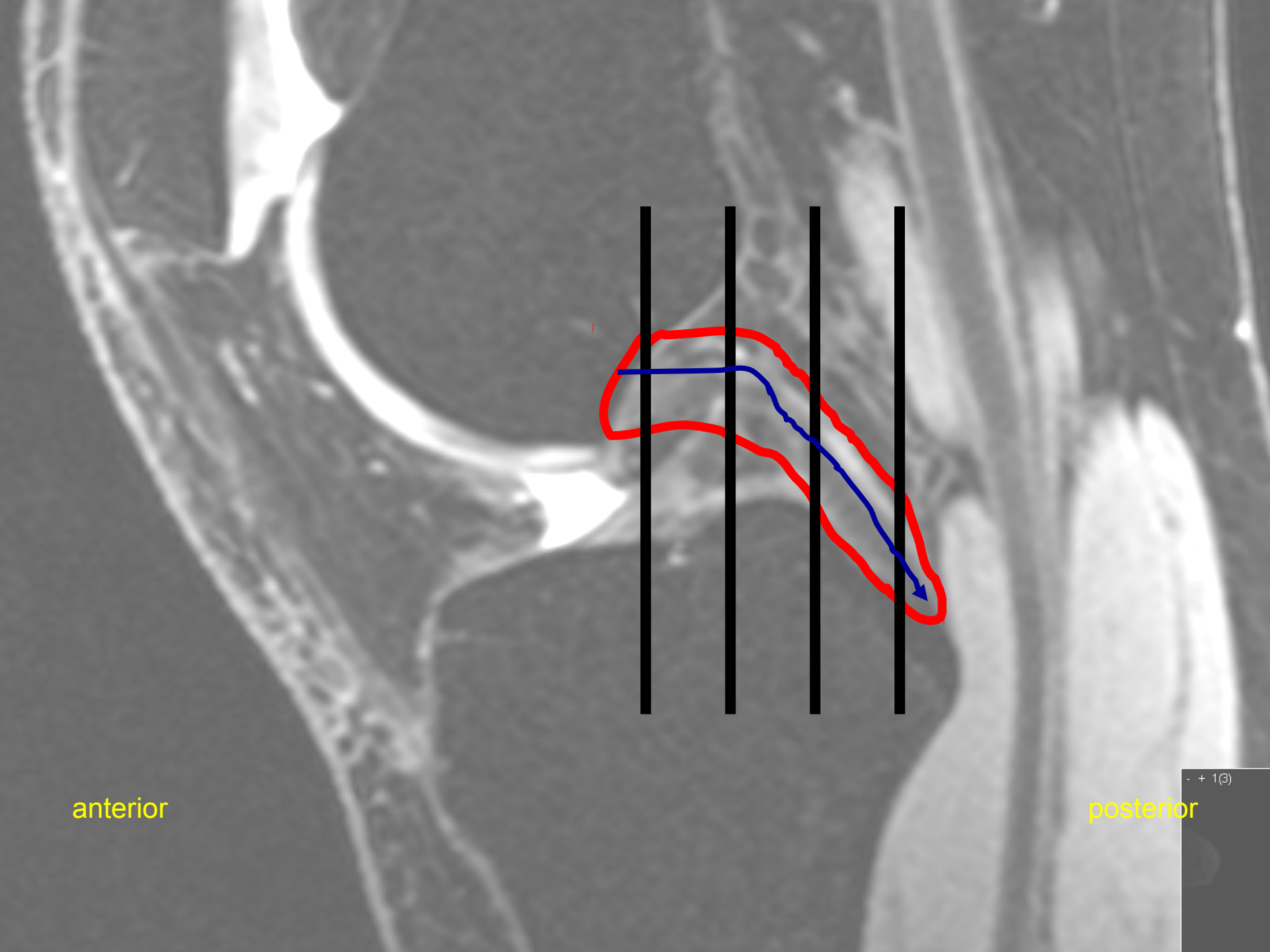


PCL

ACL

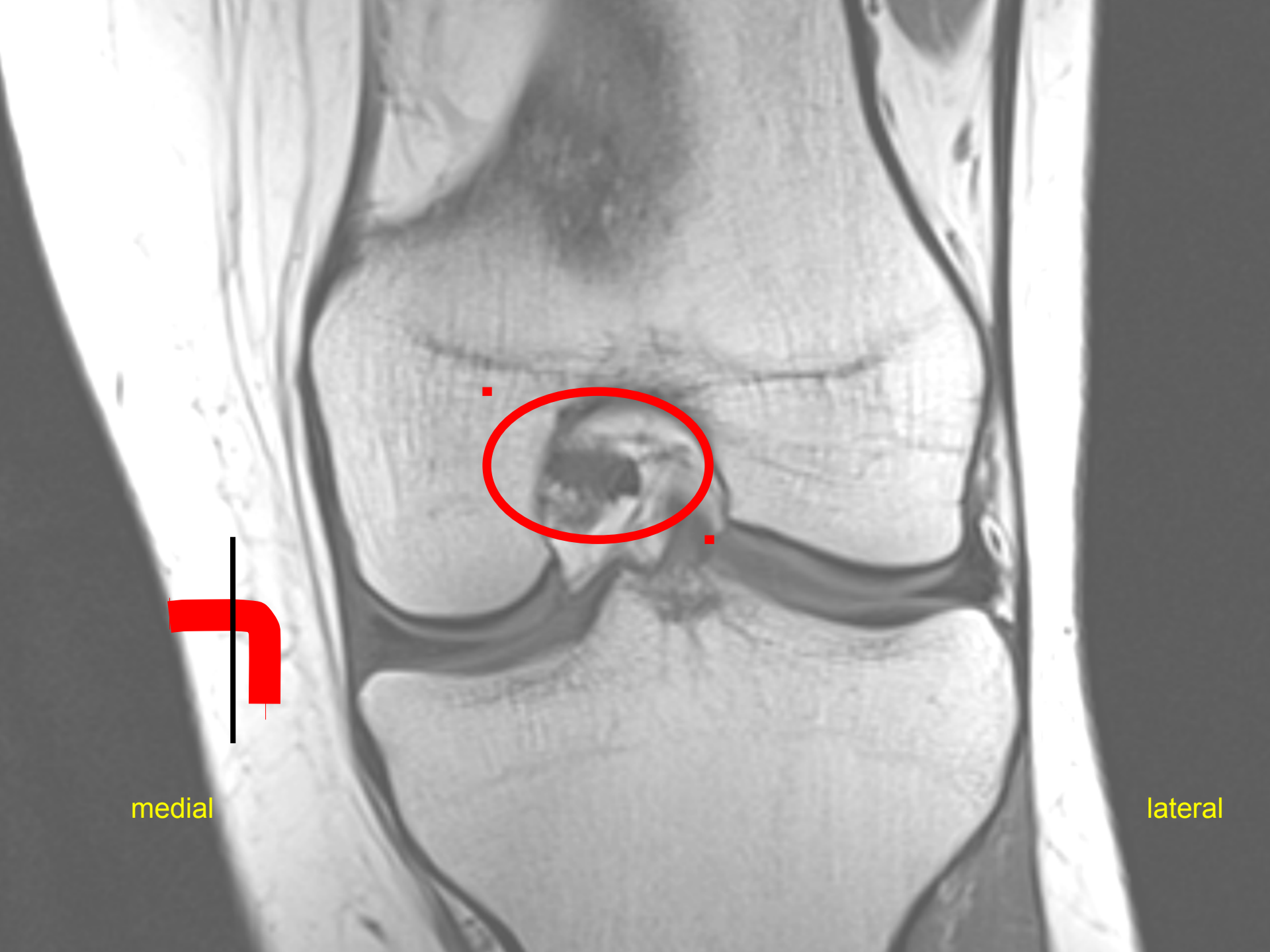
medial

lateral



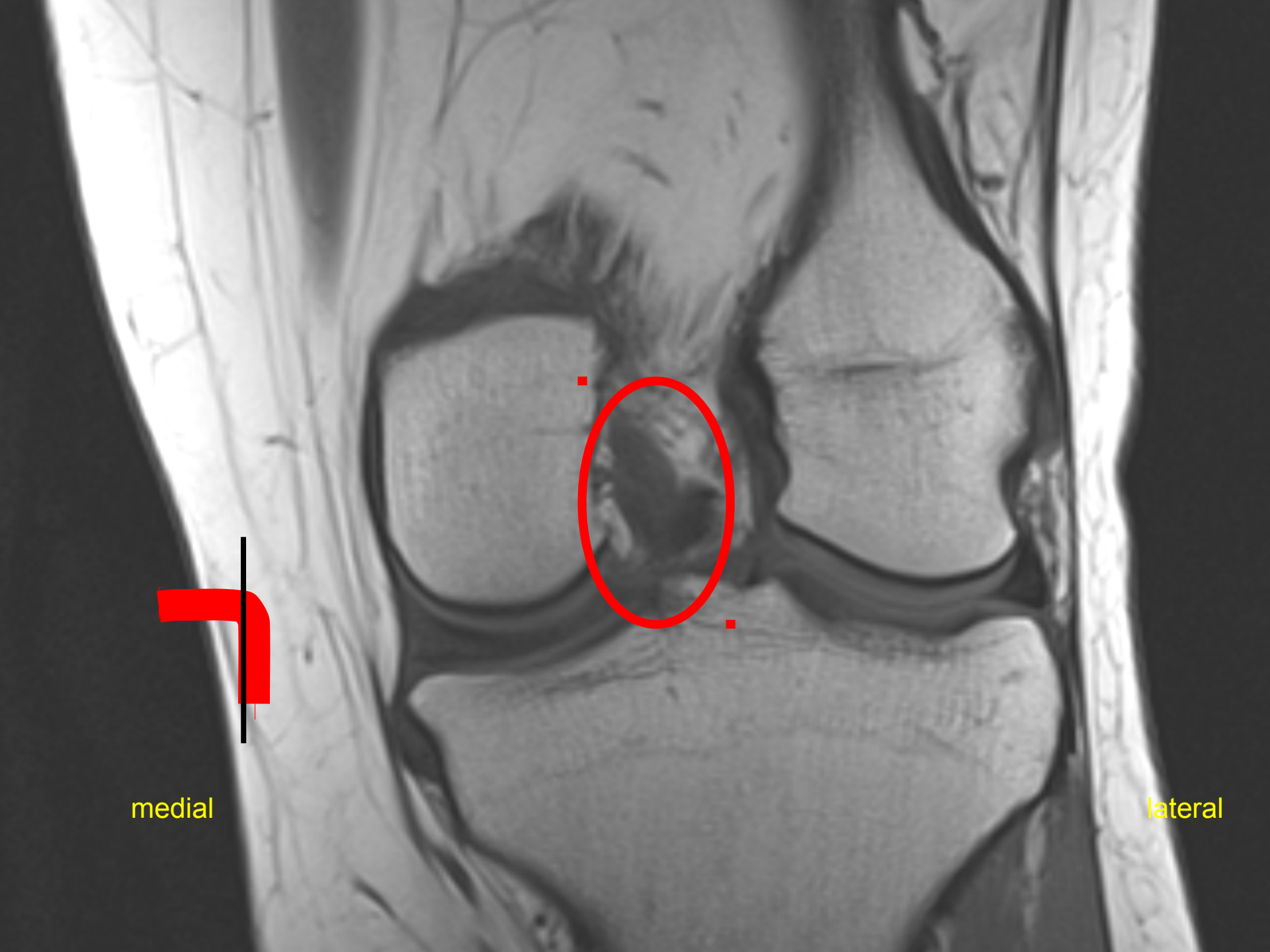
anterior

posterior



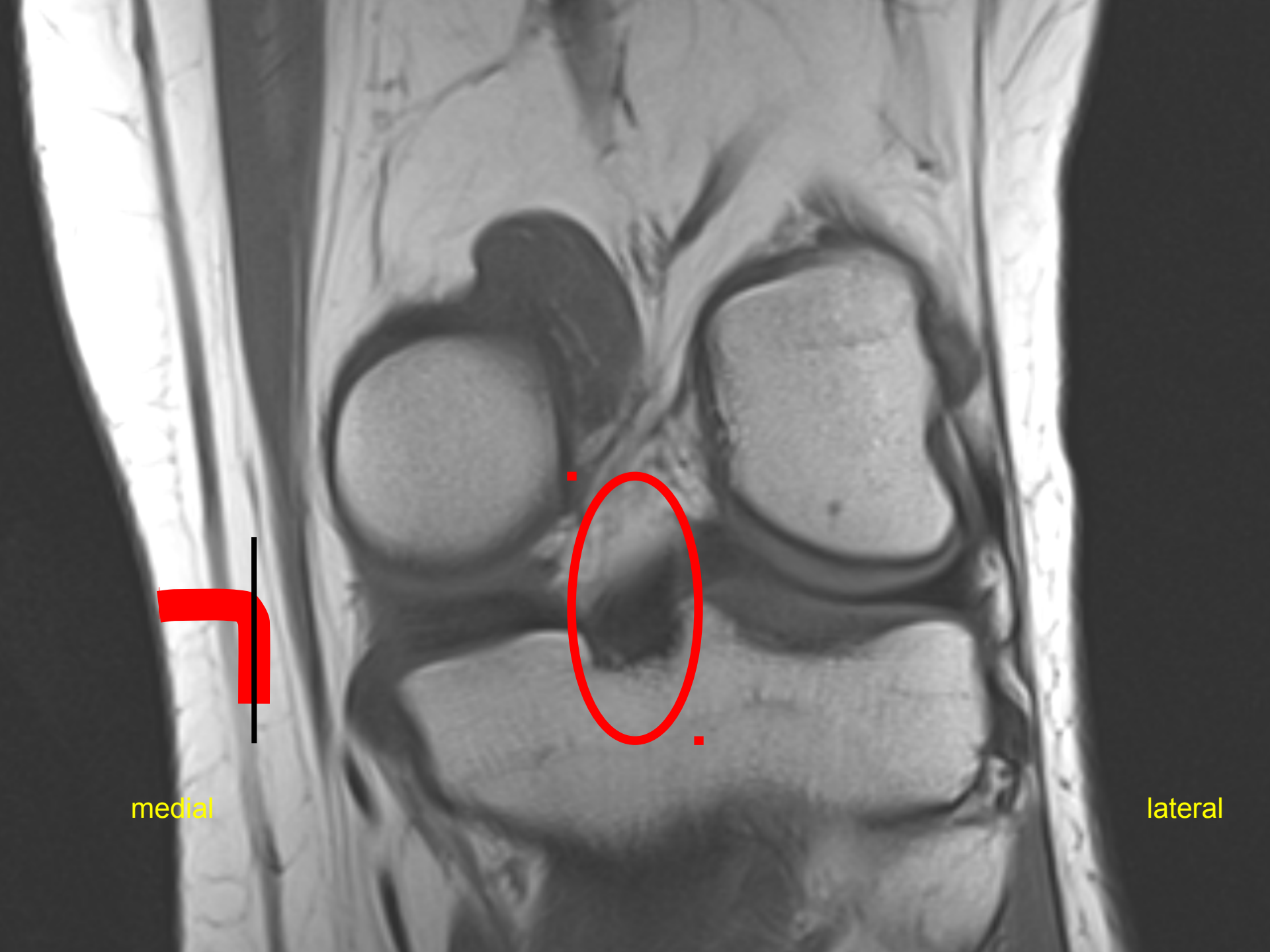
medial

lateral



medial

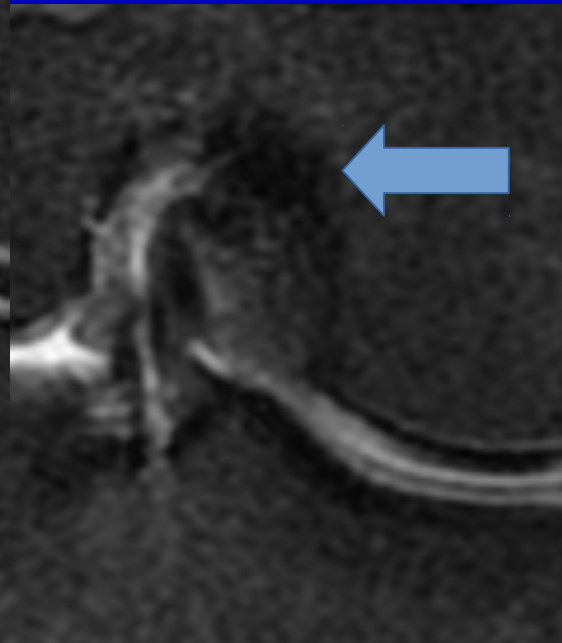
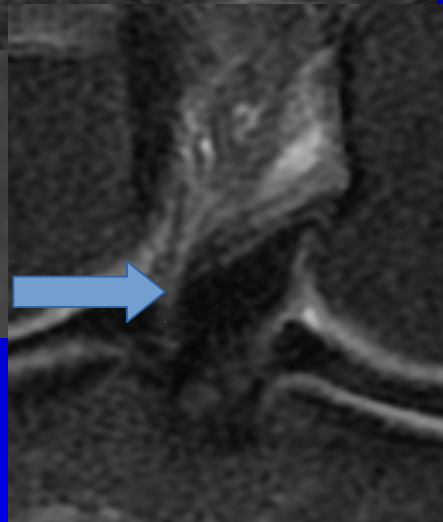
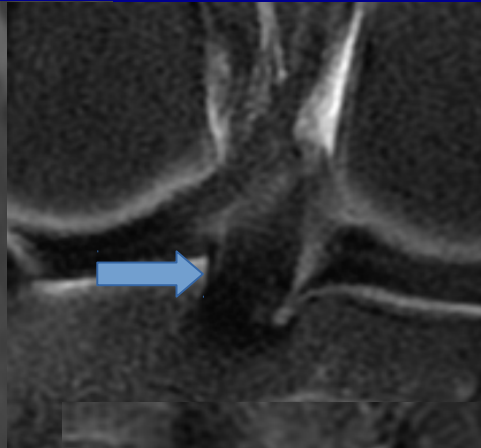
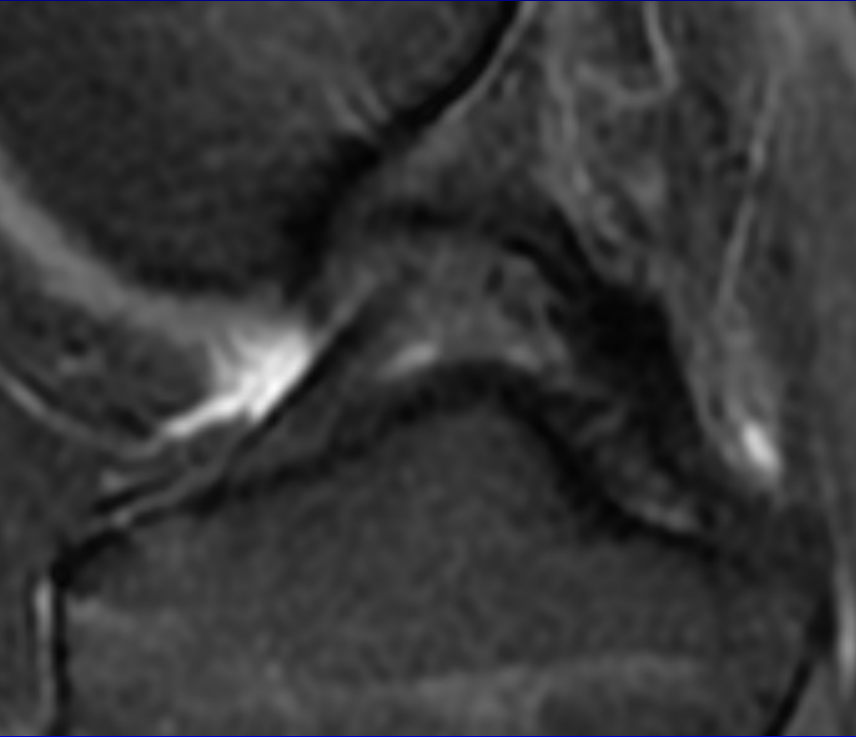
lateral

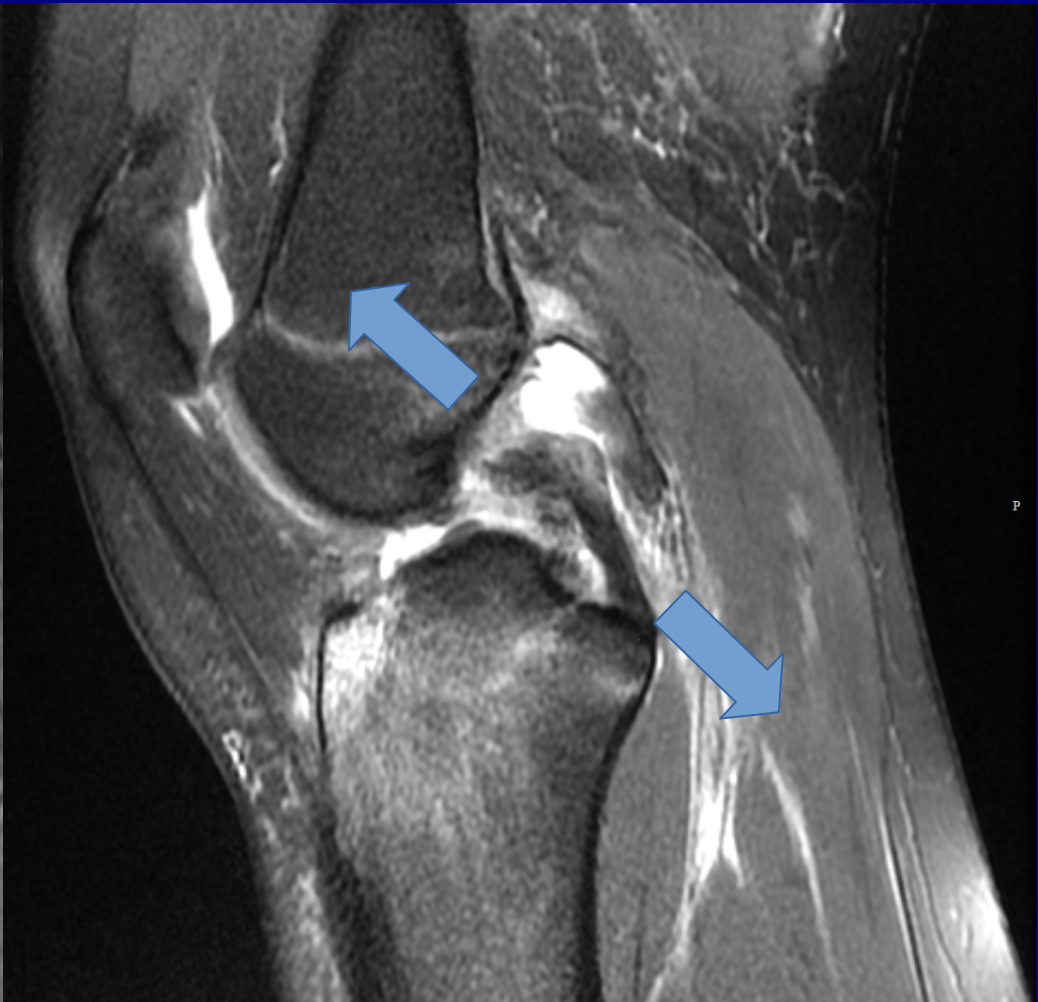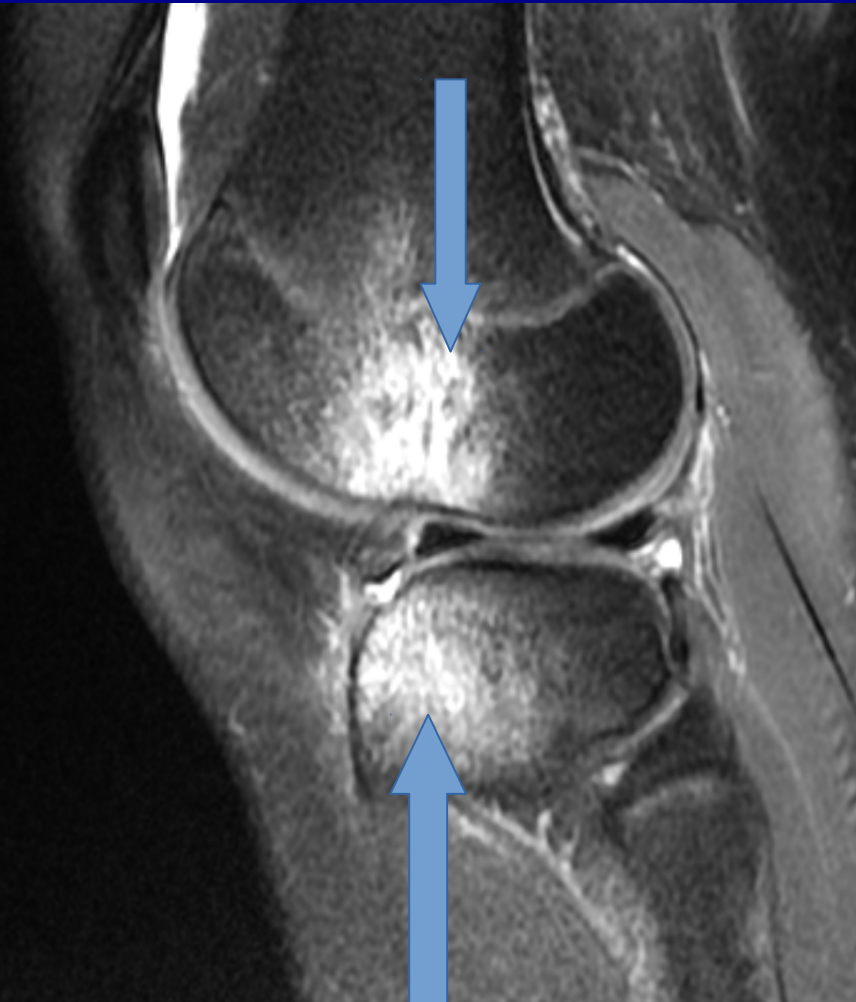


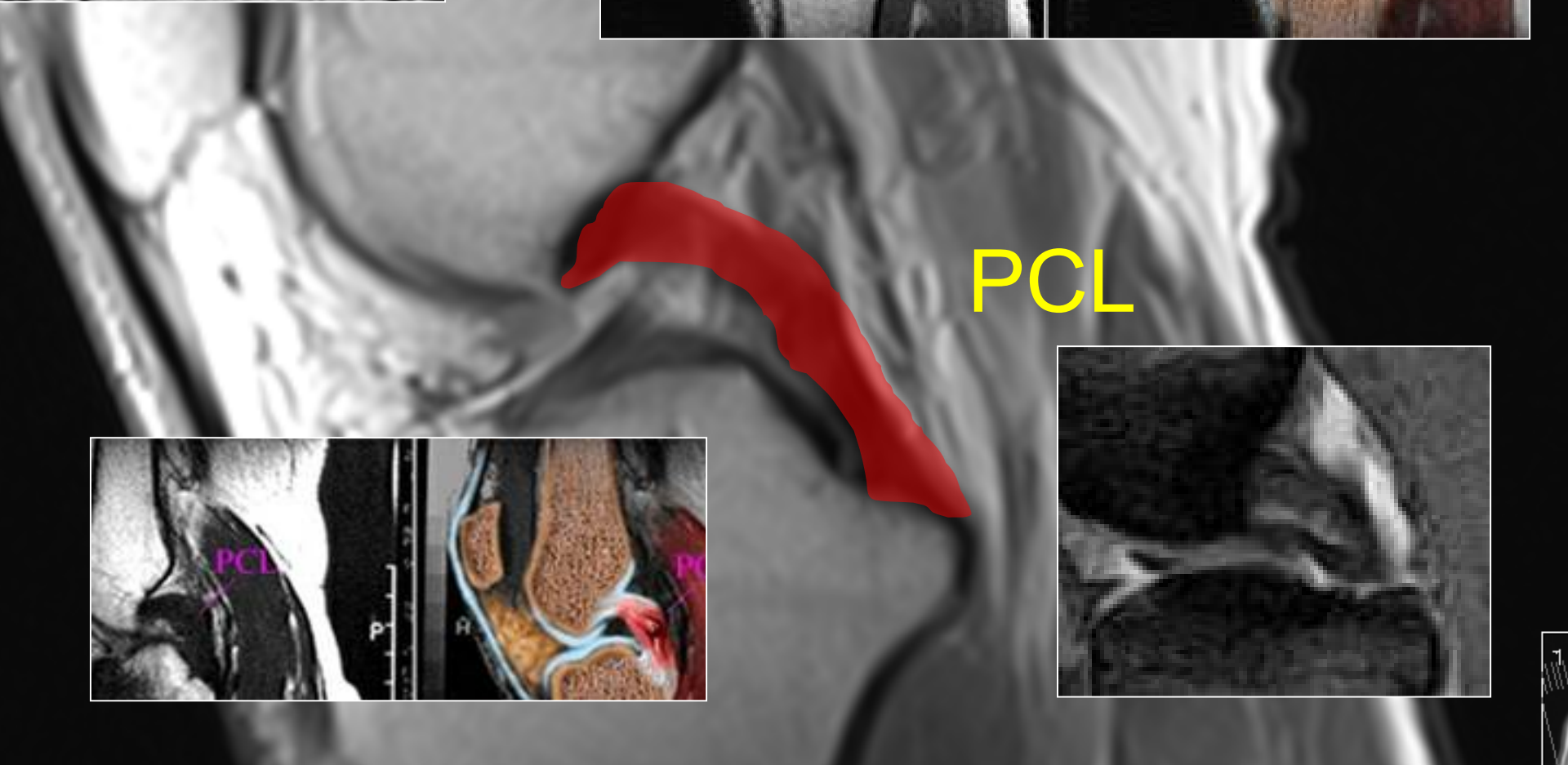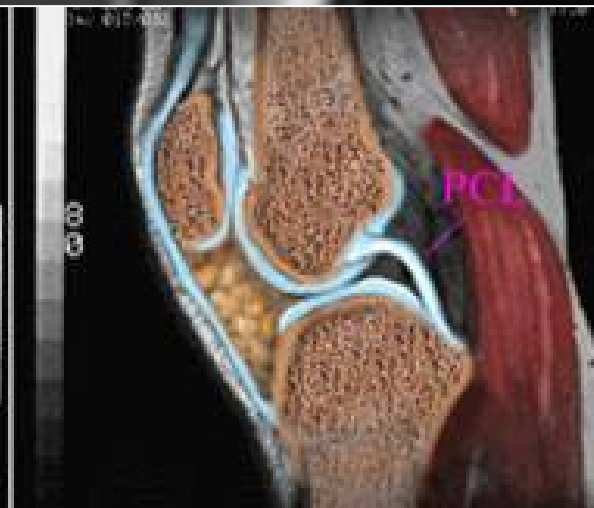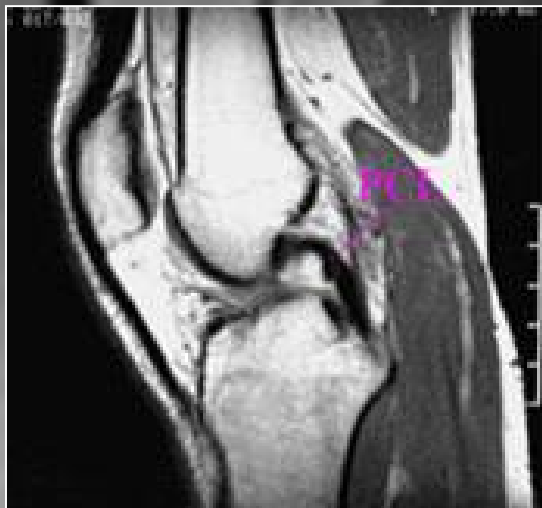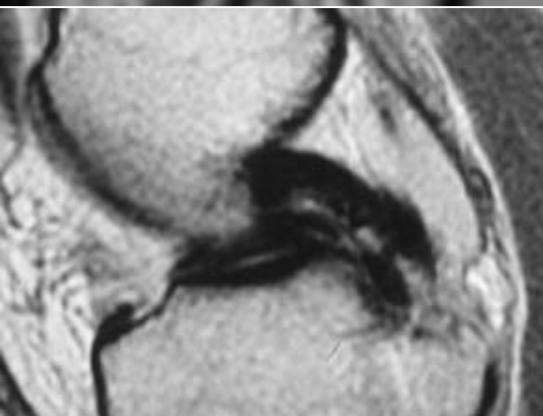
medial

lateral

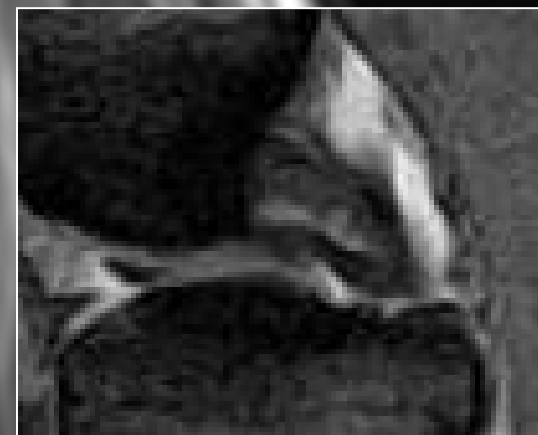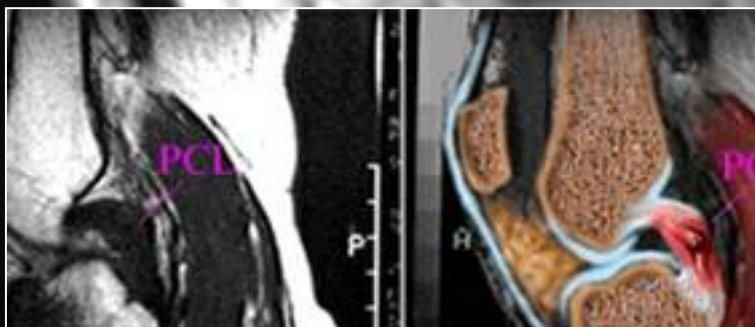
PCL Coronale bilder!



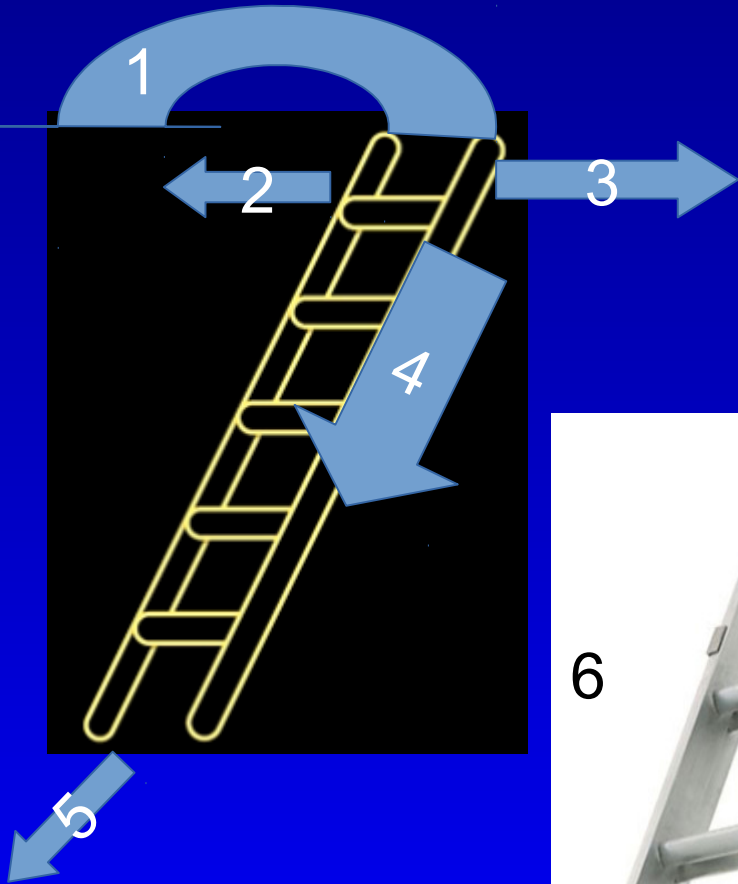




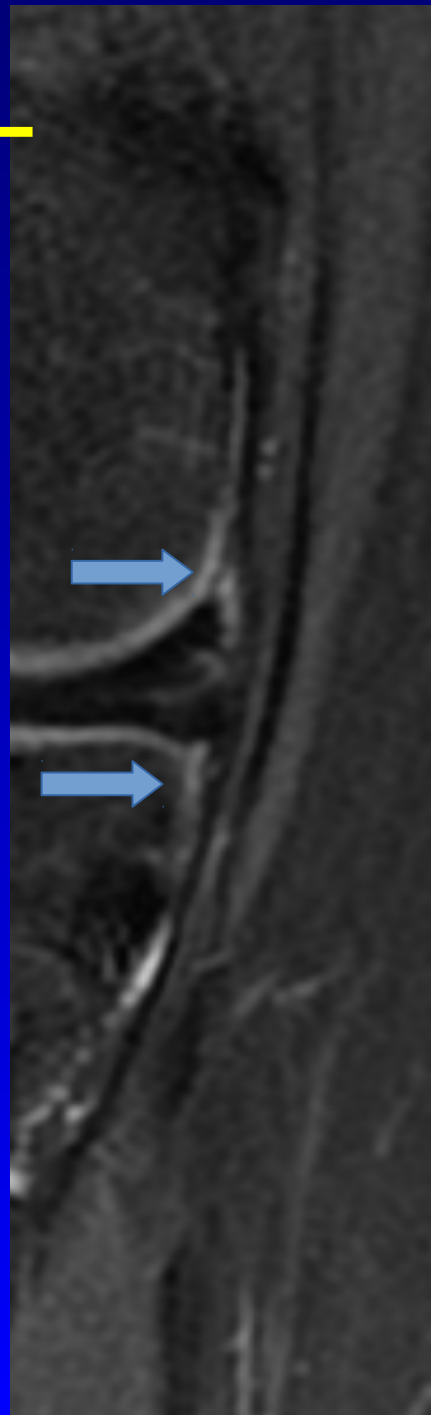
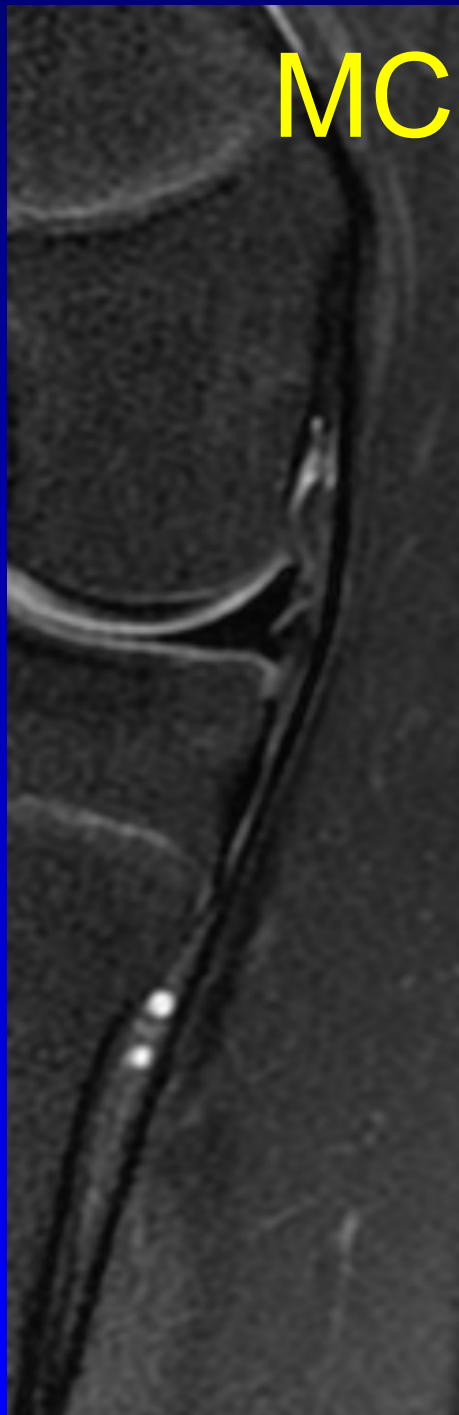
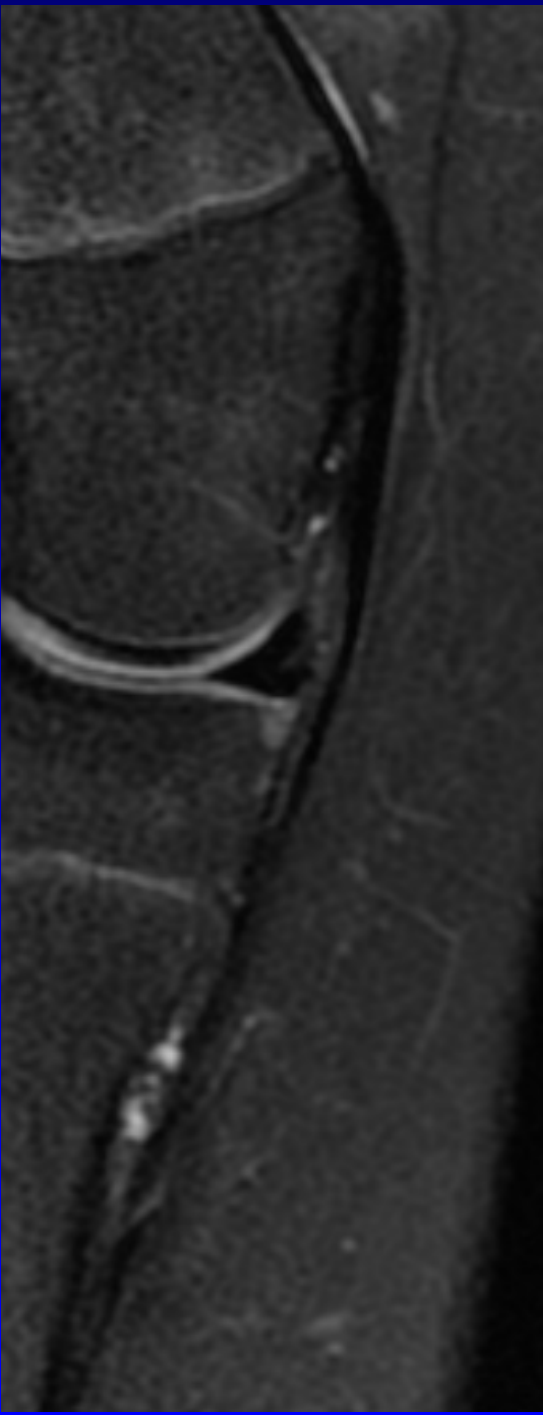
PCL



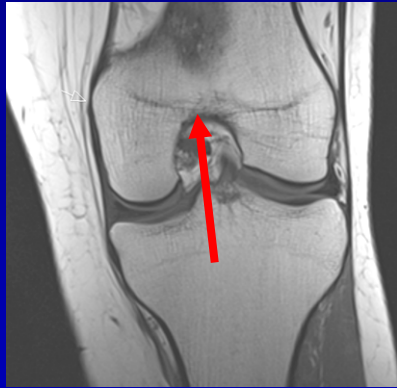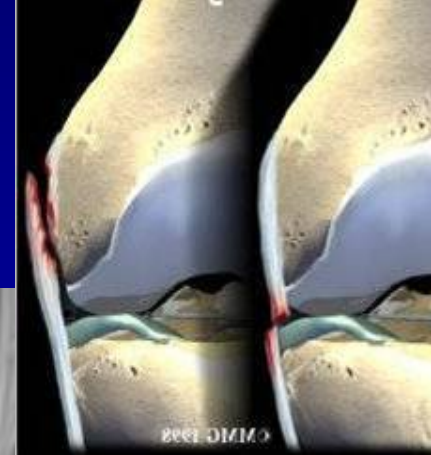
Stige med 7 muligheter



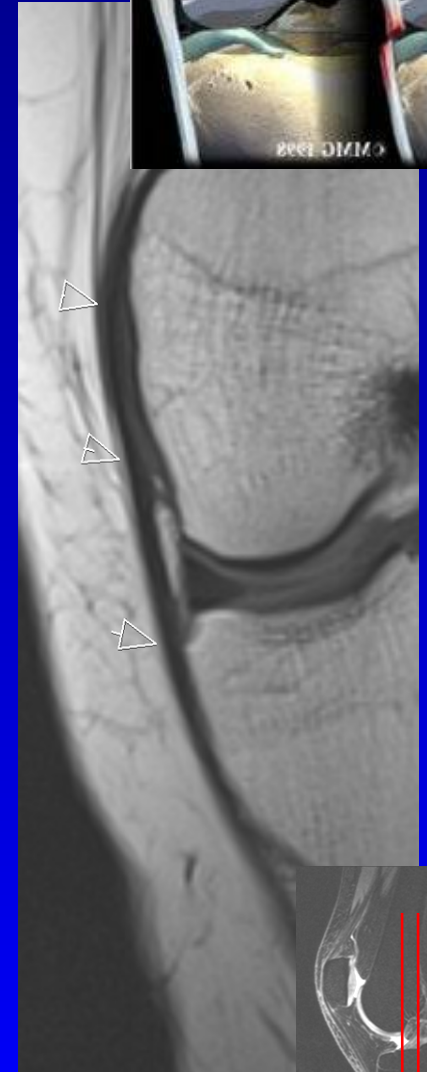
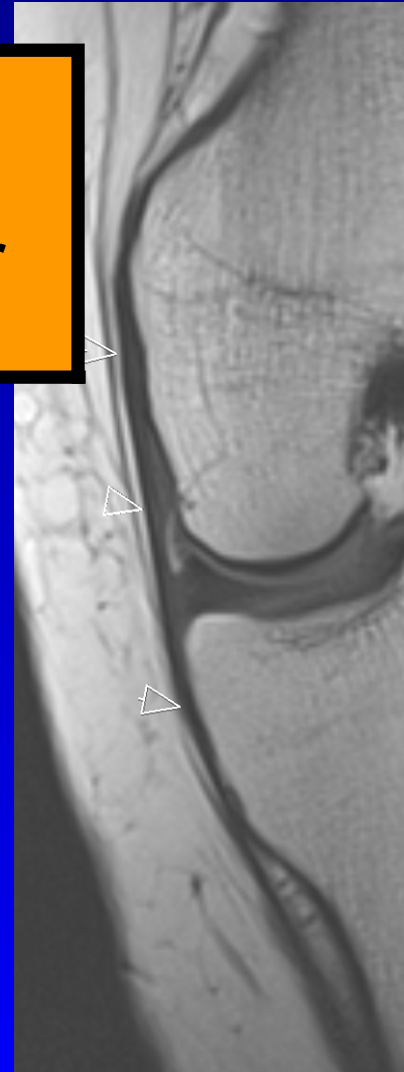
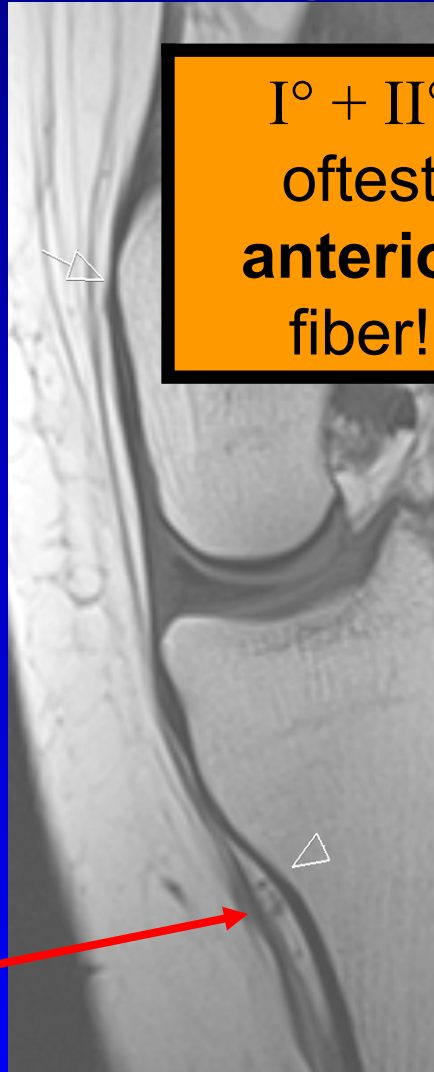MCL



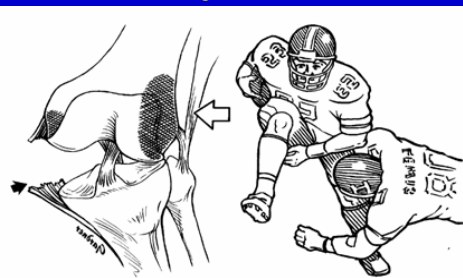
MCL Medial Collateral Ligament



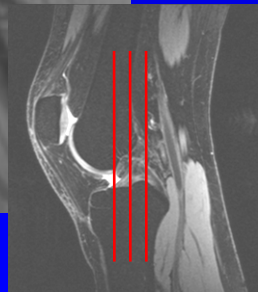
I° + II°
oftest
anterior
fiber!



•Fusjon av
femoral
kondyler

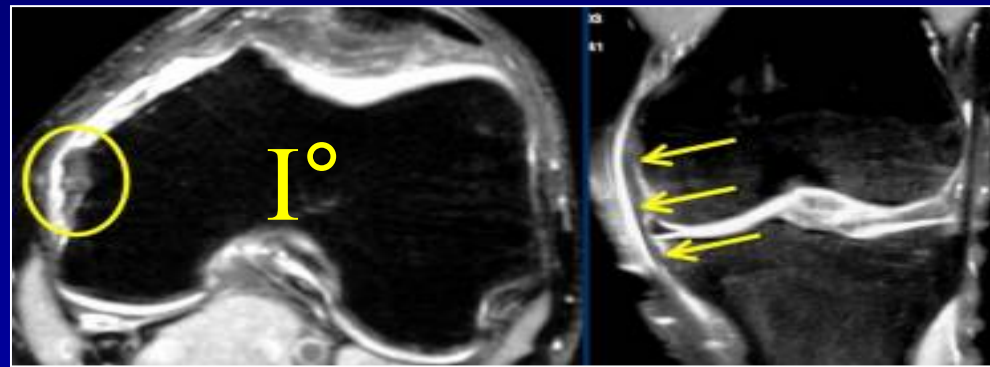


Landmerke:
arterie og 2 vener
inferiomedialis genus



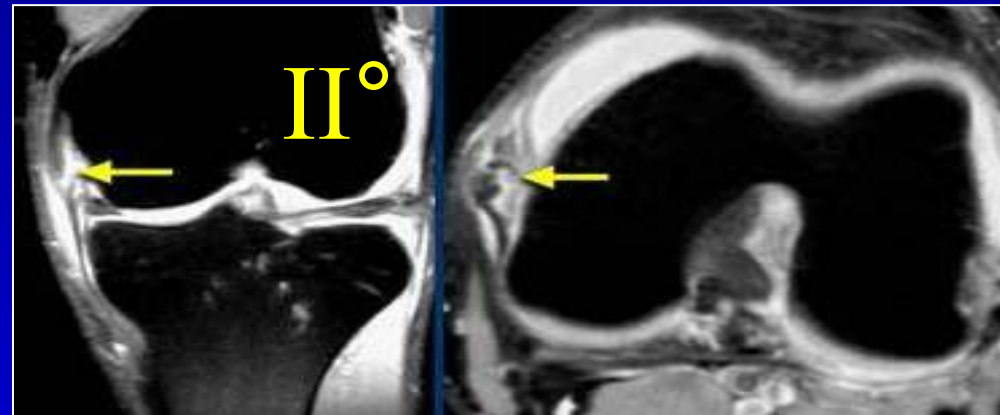
Grad 1: øm, stabil

MR: ødem superficielt,
normal tykkelse



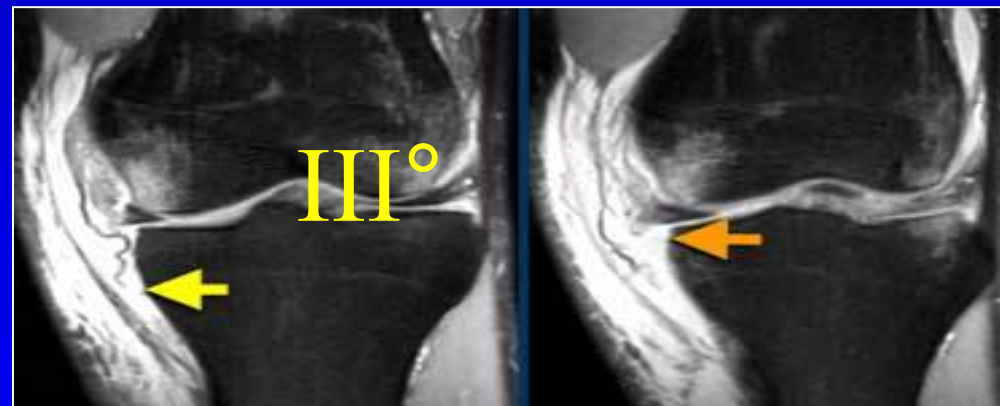
Grad 2: slakk, men med
fast endepunkt

MR: ødem på begge
sider og inne i
ligamentet, økt tykkelse,
skiller seg fra kortikalt
bein.

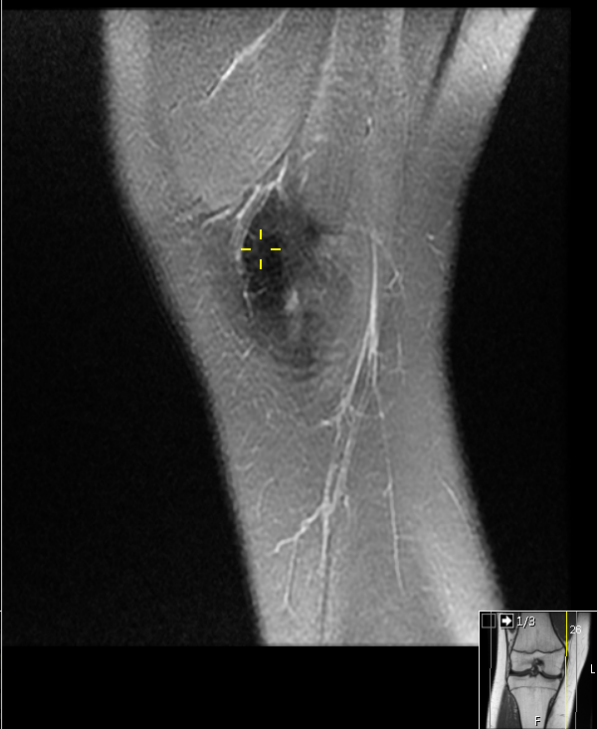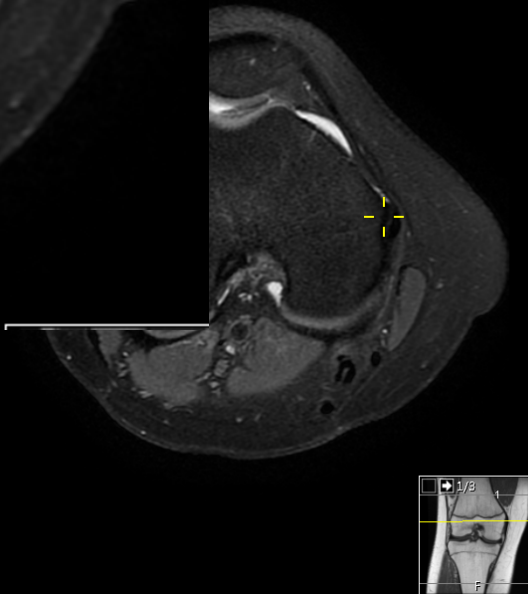

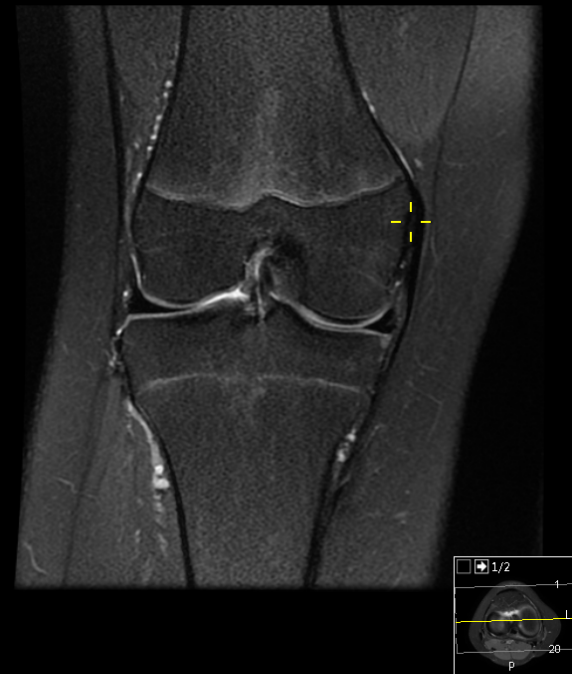
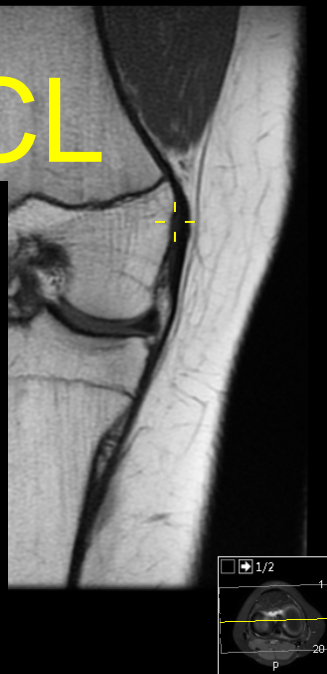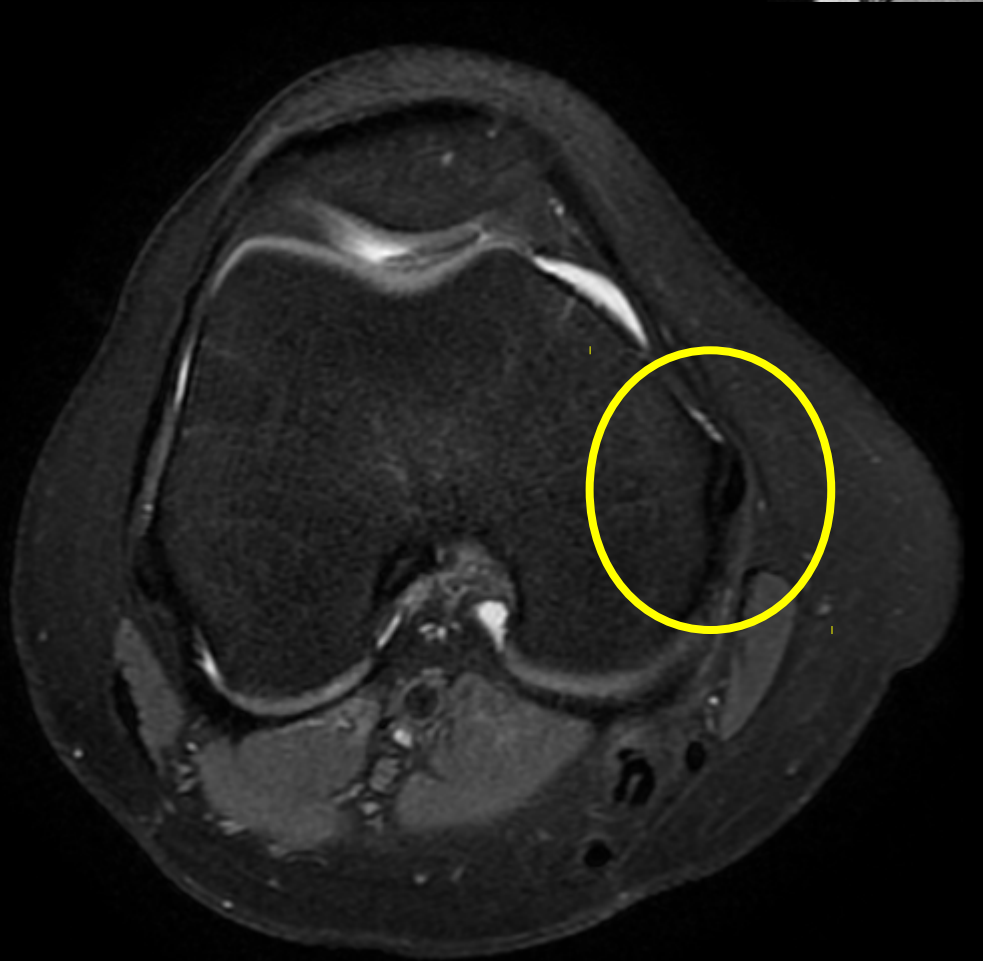Grad 3: ruptur, instabil


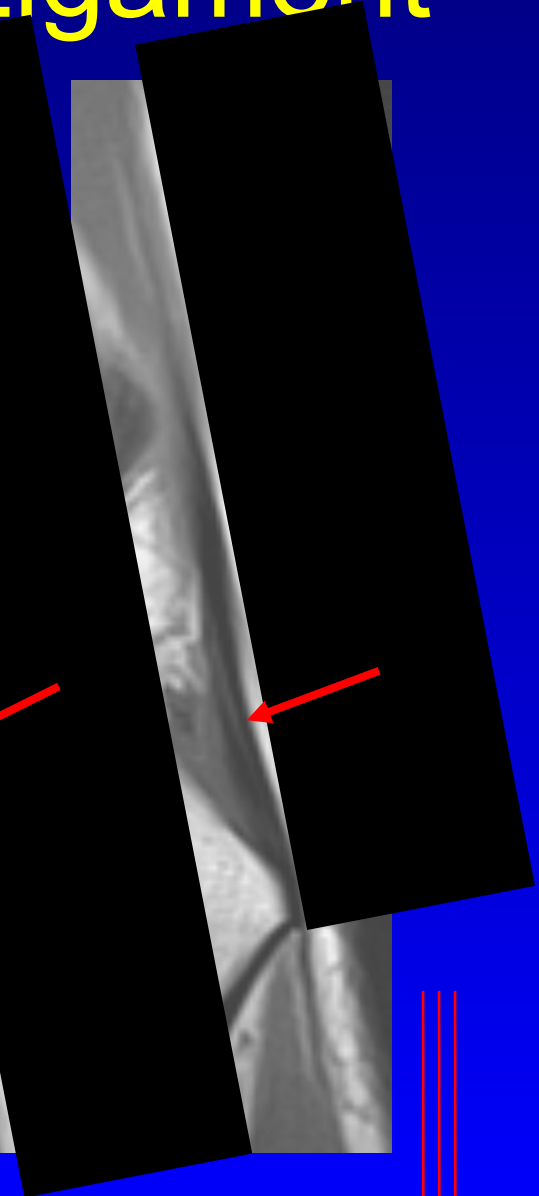
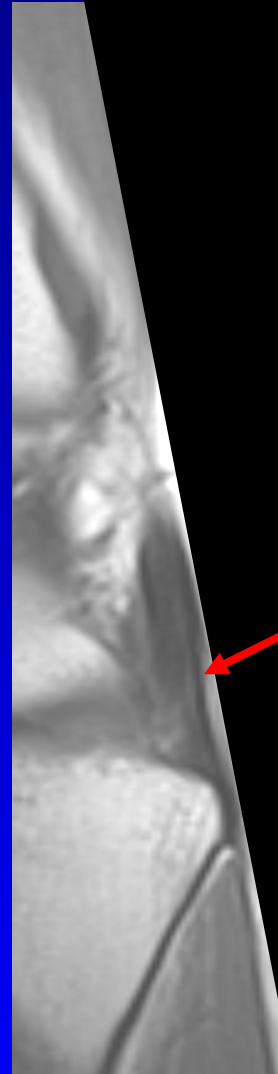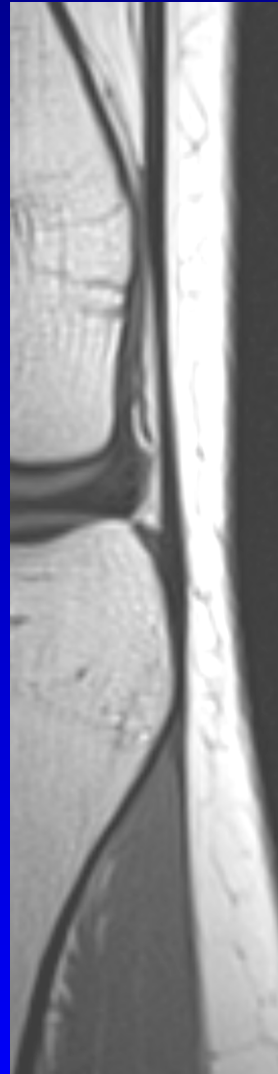
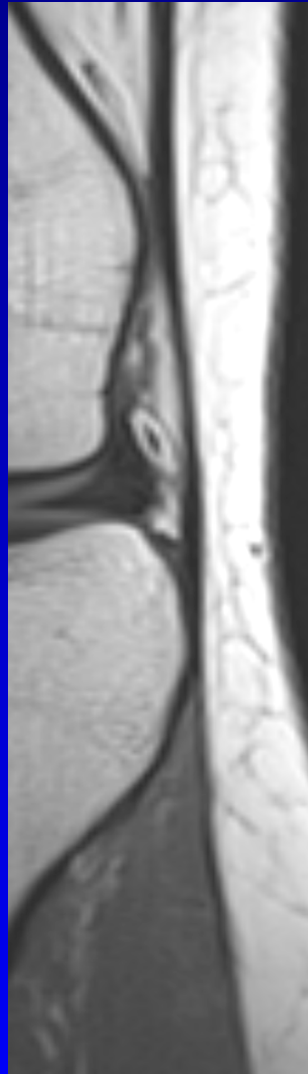
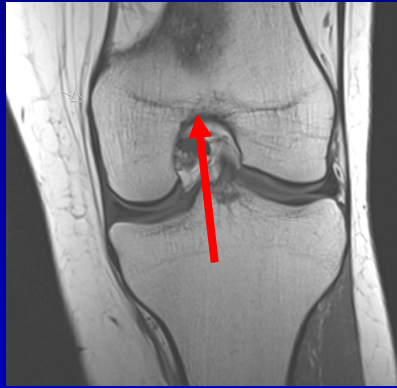
MR: diskontinuitet



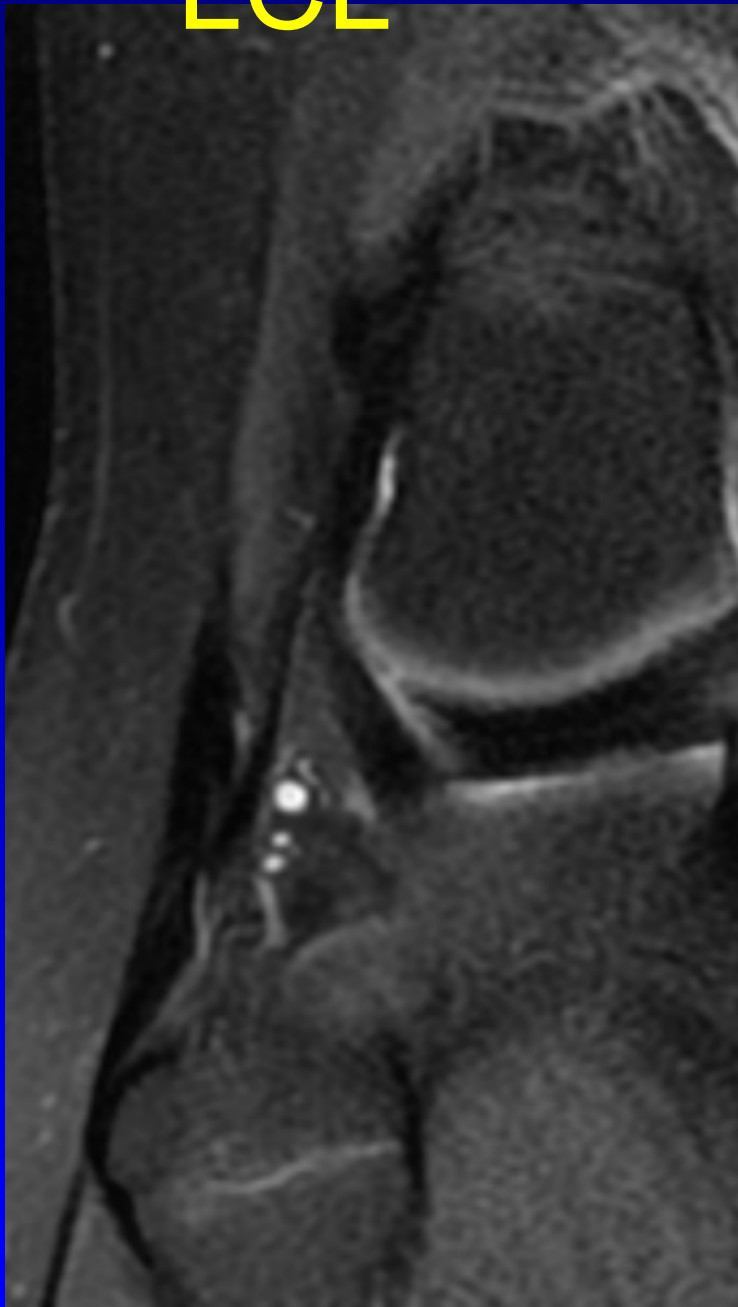
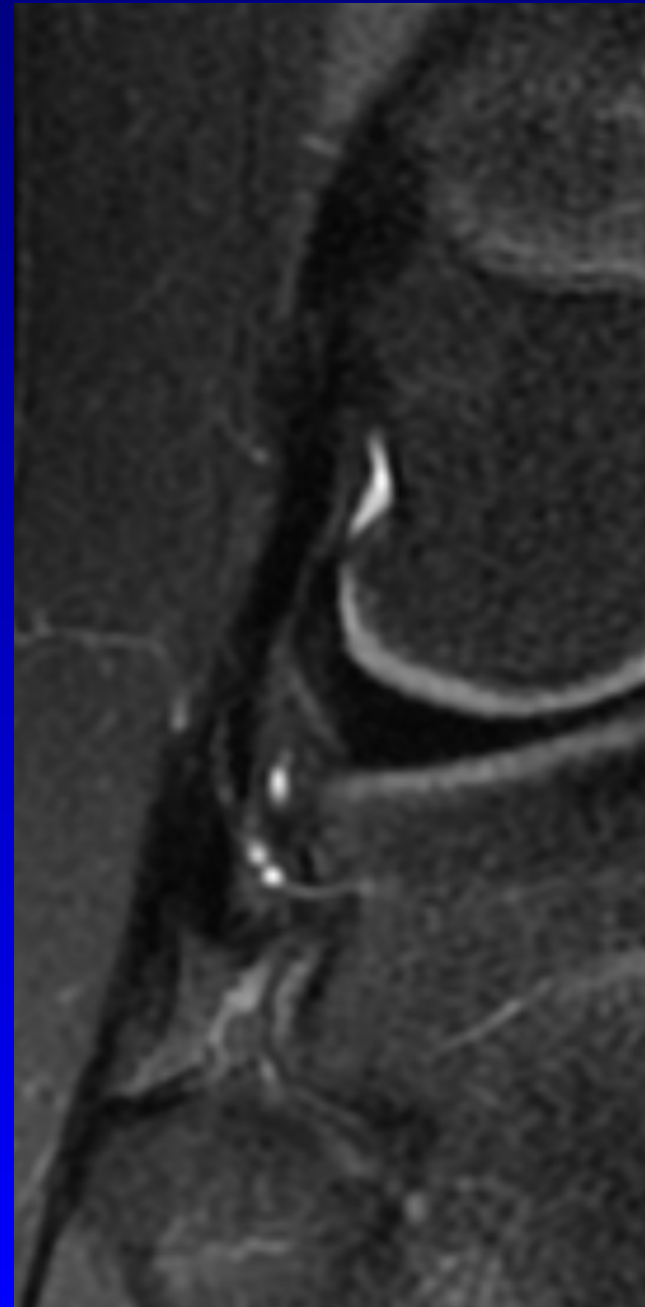
MCL



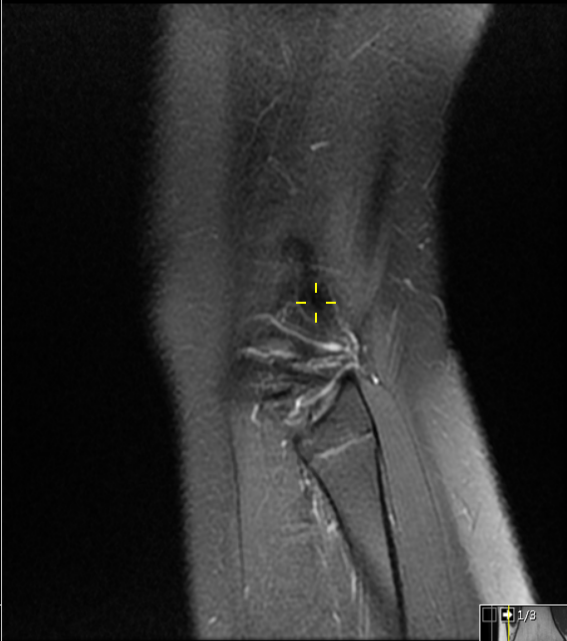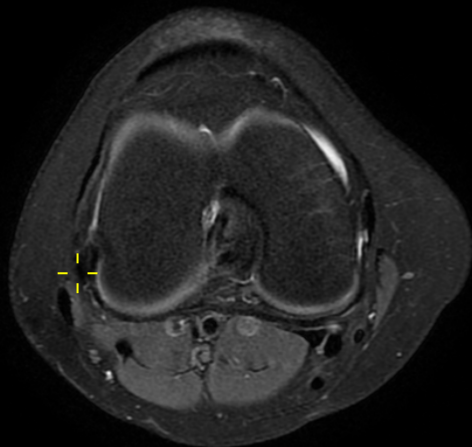
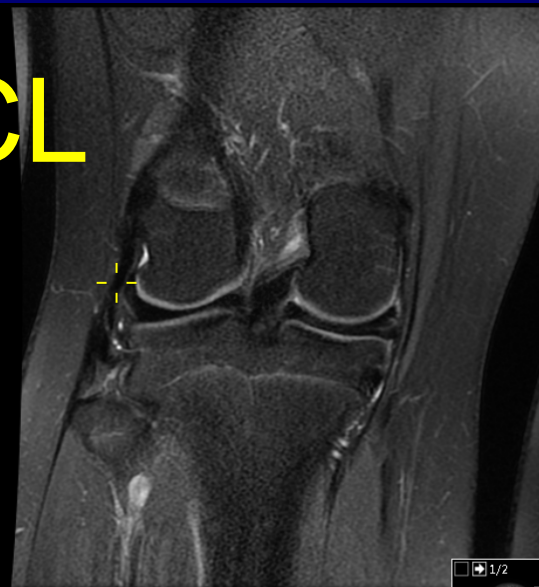
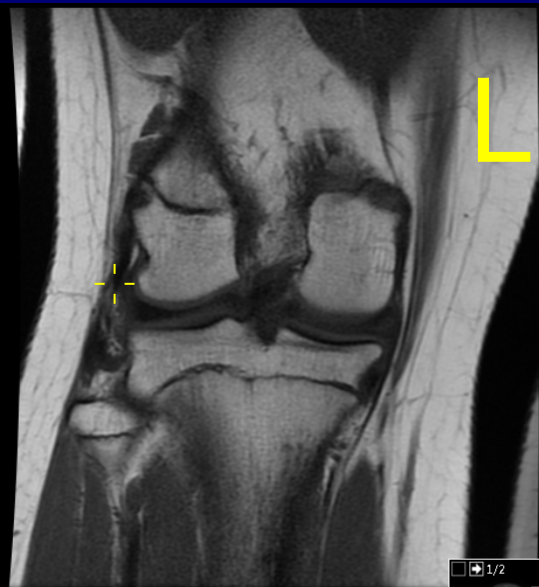
LCL Lateral Collateral Ligament



LCL



LCL



Bløtvev

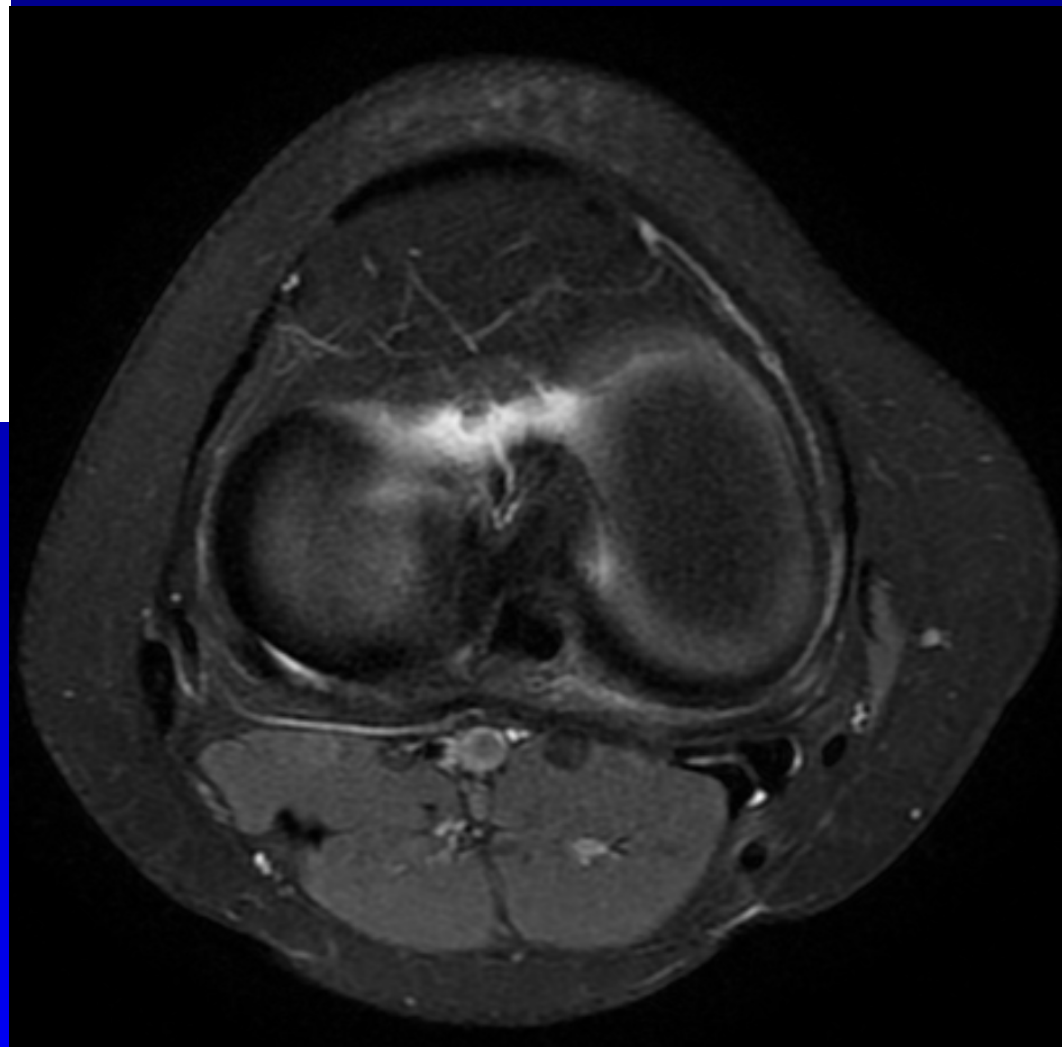
Muskulatur N/ødem/ruptur/
hematom

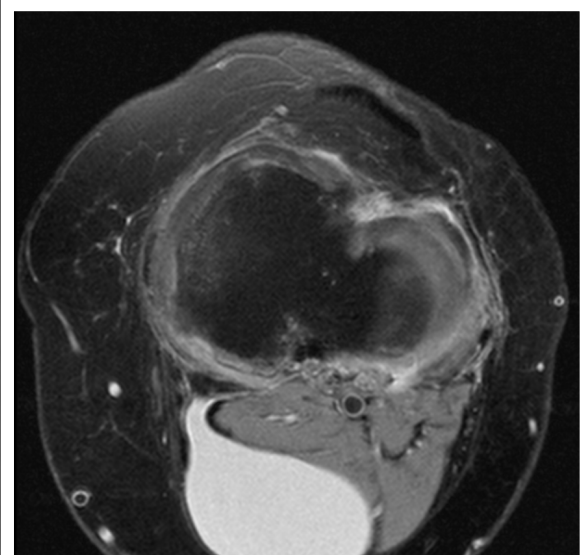
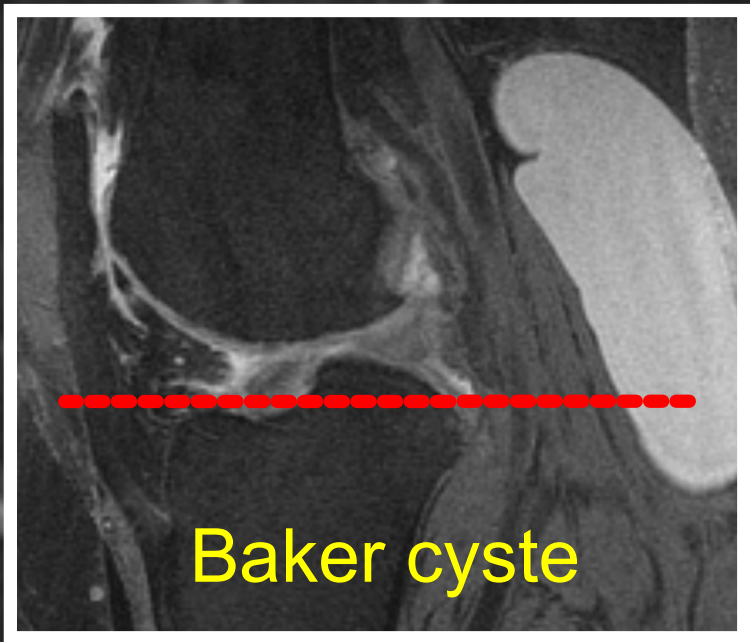
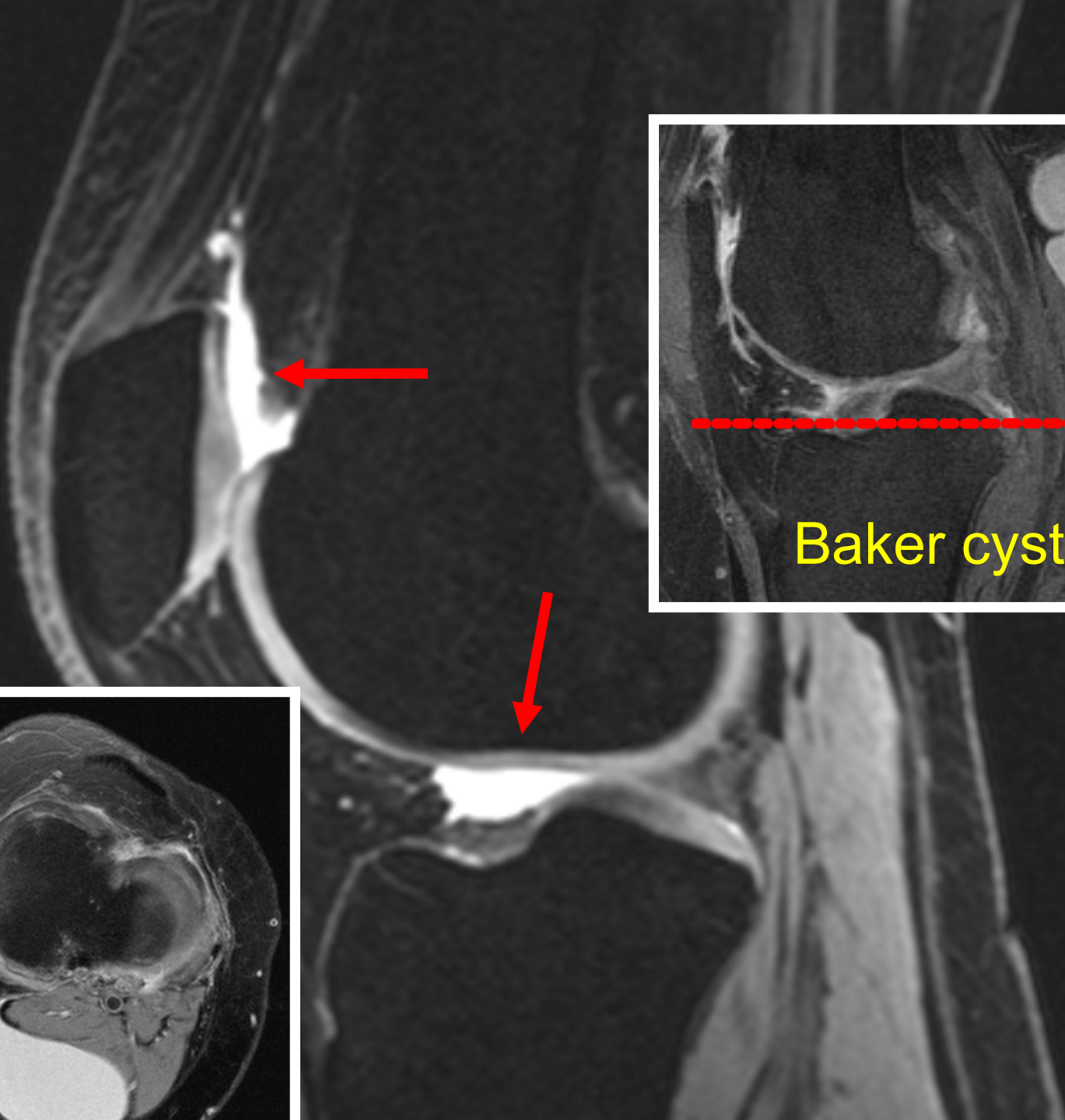
Væske hydrops

Bakers cyste størrelse/lekkasje

Gastroknemius/Pes
anserinus størrelse/synovitt/
chondromatose

**Nevro vaskulære
strukturer** N/aneurysma/
nevrinom





MR KNE

Fremre kammer

Upåfallende patella form, størrelse og beliggenhet. Upåfallende benmargssignal og retropatellære brusk.

Upåfallende quadricepssene, patellasene og Hoffas fettpute

Mediale og laterale kammer

Upåfallende benmargssignal, leddoverflater og brusk. Intet å bemerke ved mediale og laterale menisk.

Fremre og bakre korsbånd er upåfallende.

Mediale og laterale kollateralligameter er upåfallende.

Intet å bemerke ved muskulatur og nevrovaskulære strukturer.

Ingen hydroks eller Bakers cyste.

R: Intet å bemerke.



NFMSR

NORSK FORENING FOR MUSKEL- OG SKJELETTTRADIOLOGI ©

Volker Lapczynski

Nestleder NFMSR

Muskel- skjelettradiolog

Unilabs Røntgen Fredrikstad

vl@Radiology.no

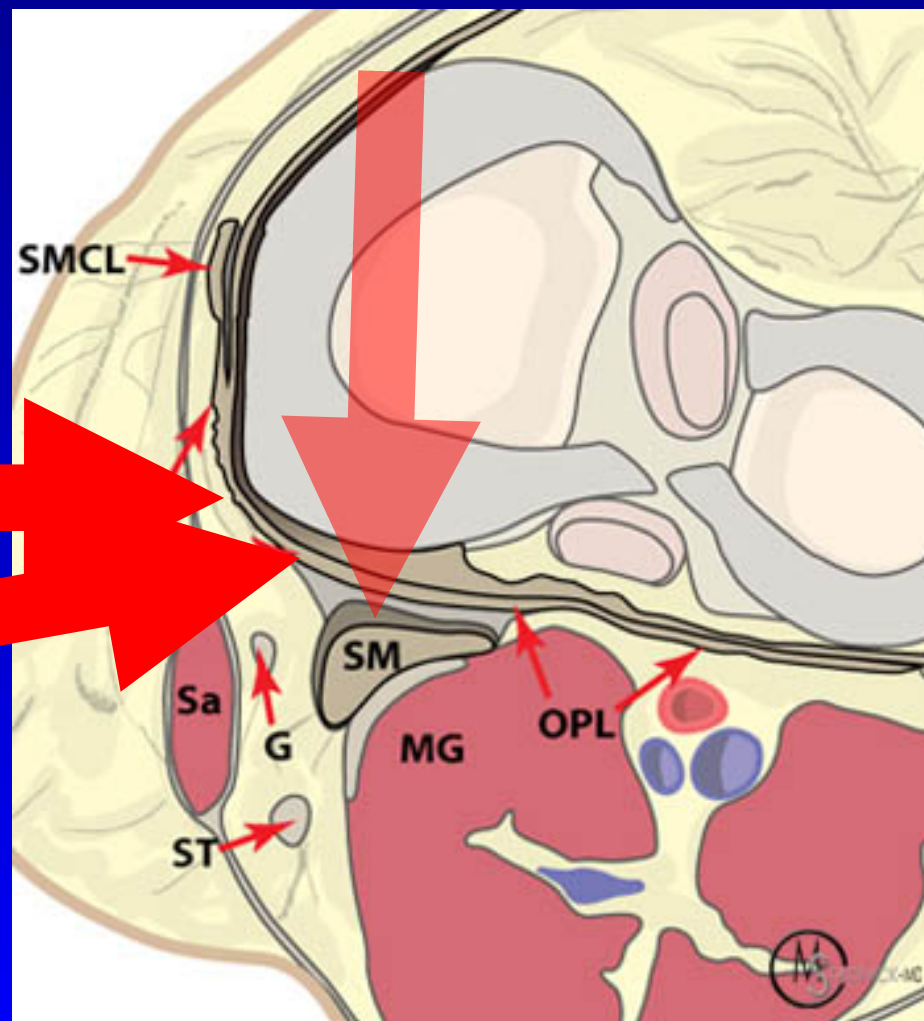
Radiology.no/msk/

Posteromediale hjørne PMC

Semimembranosus N/tendinopati/ruptur sene

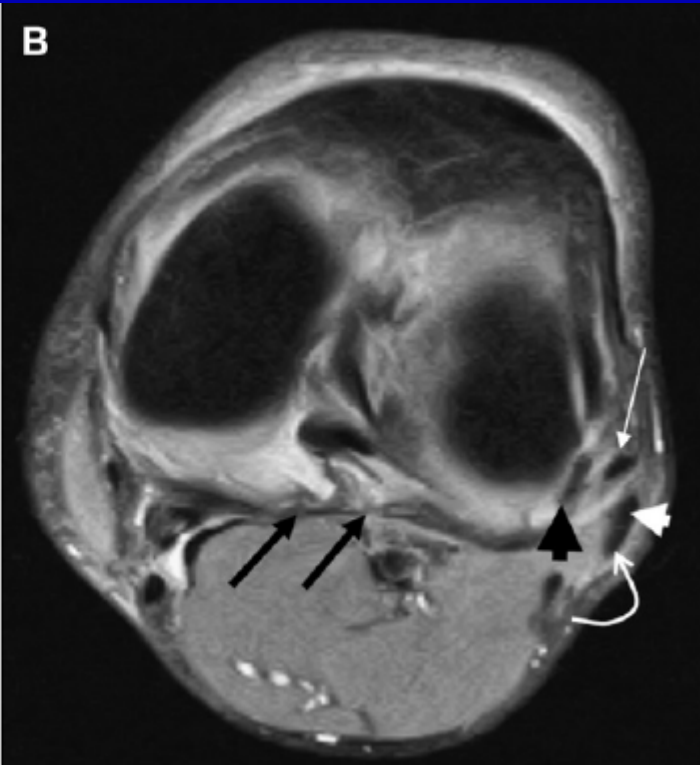
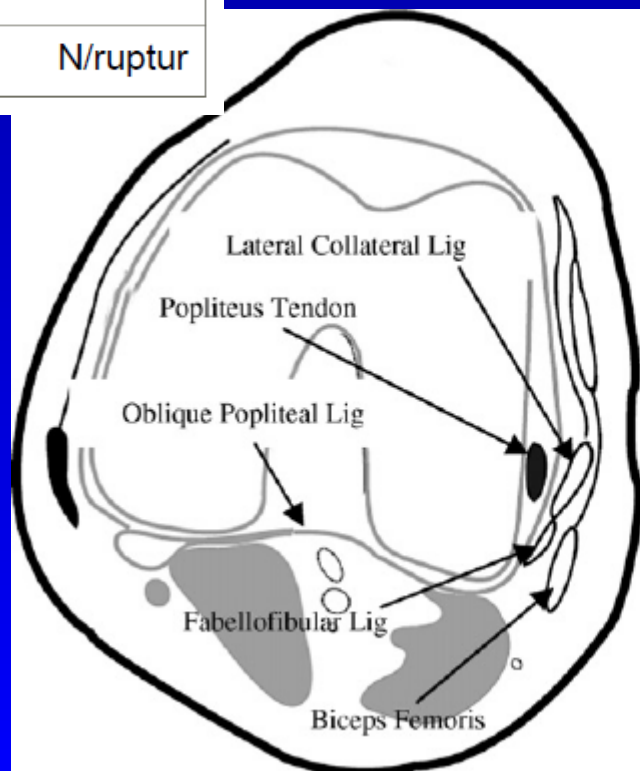
Post. oblique lig. N/tendinopati/ruptur POL

PM leddkapsel N/ruptur



Posterolaterale hjørne PLC

1 Popliteus sene	N/tendinopati/ part. ruptur
2 Biceps femoris senen	N/tendinopati/ part. ruptur
3 Popliteofibulare ligament	N/tendinopati/ruptur
4 LCL	N/tendinopati/ruptur
5 Tractus iliotibialis TIB	N/tendinopati/ruptur
6 PL leddkapsel	N/ruptur



Posterior lateral hjørne

biceps femoris

fibular kollateral ligament

f

